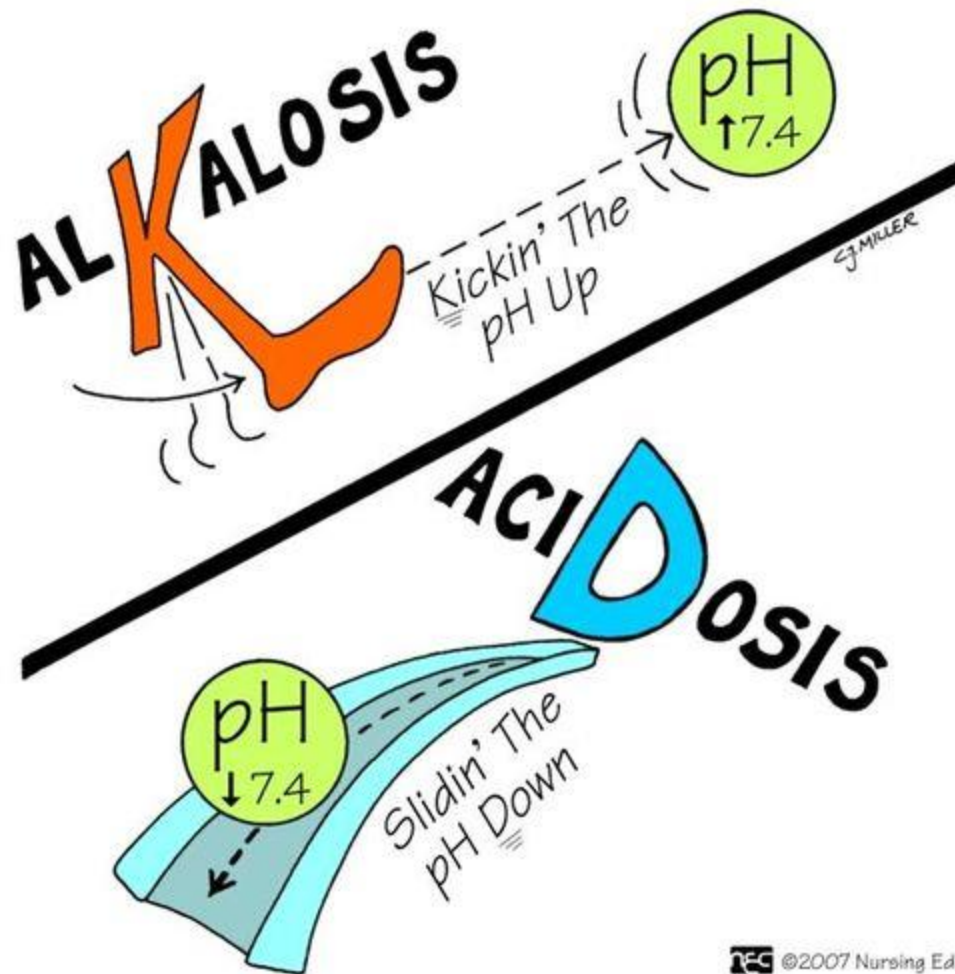
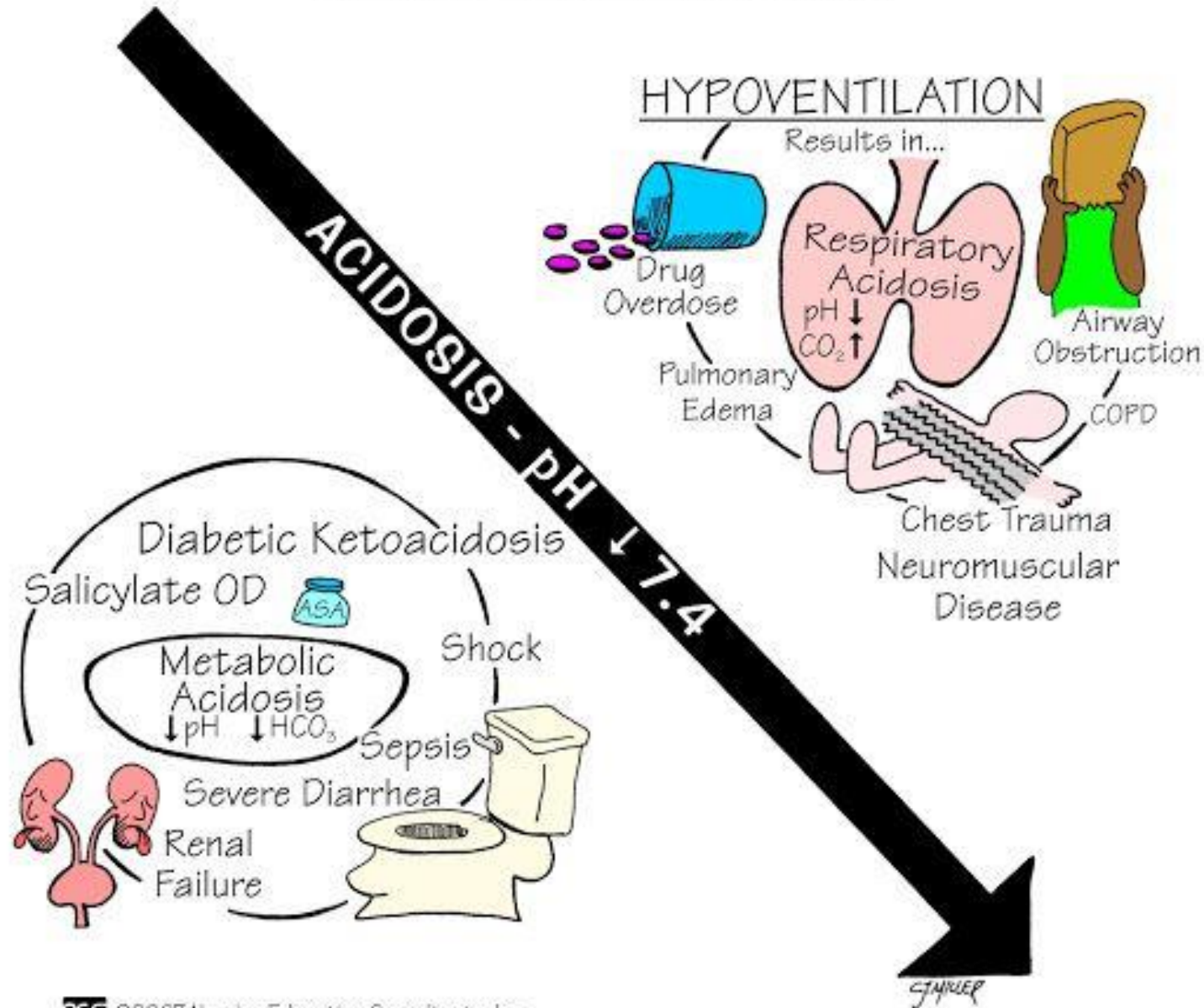


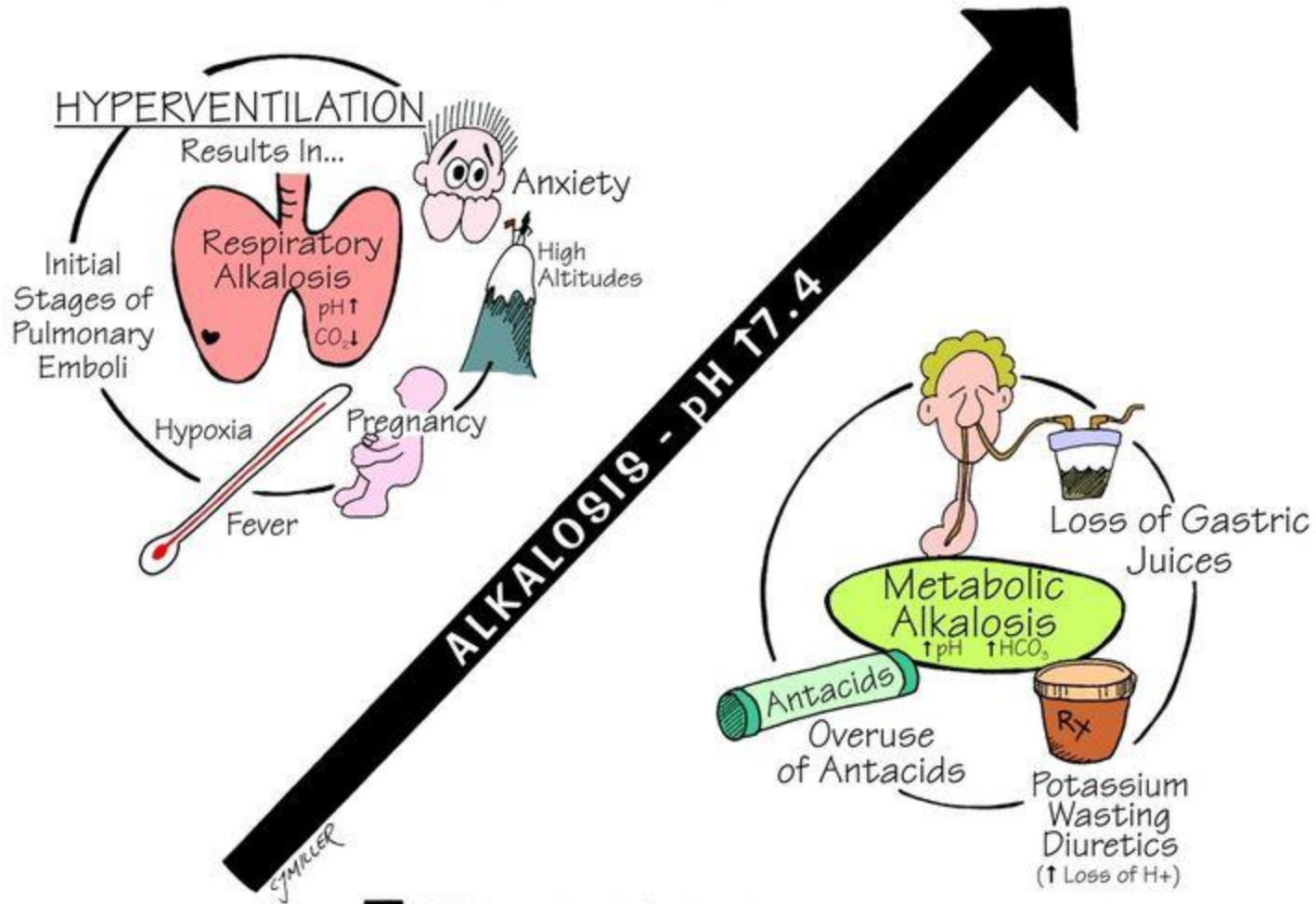
ACIDOSIS - ALKALOSIS



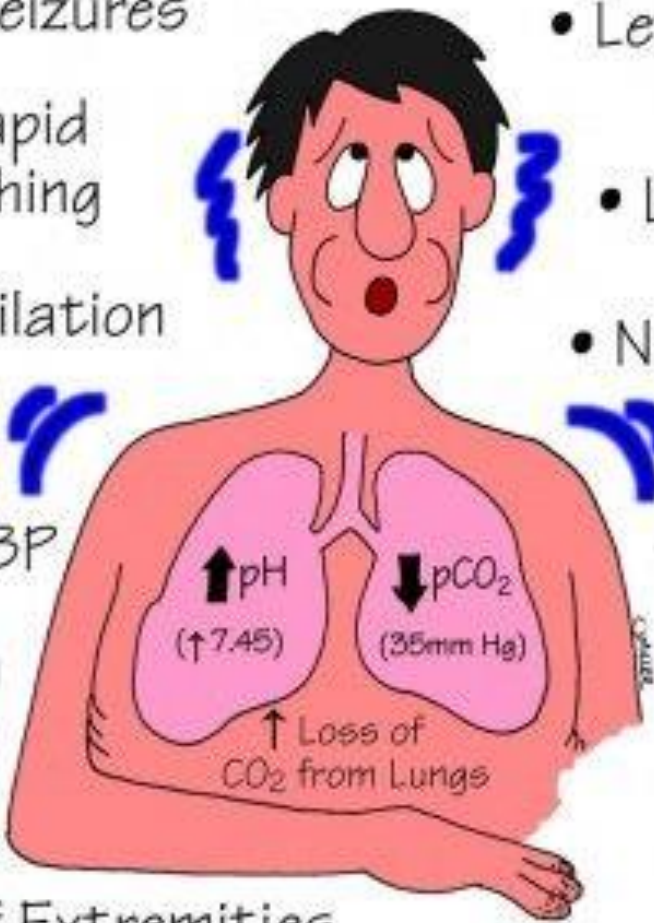
CAUSES OF ACIDOSIS



CAUSES OF ALKALOSIS



RESPIRATORY ALKALOSIS

- Seizures
 - Lethargy & Confusion
 - Deep, Rapid Breathing
 - Light Headedness
 - Hyperventilation
 - Nausea, Vomiting
 - Tachycardia
 - Causes:
 - Hyperventilation (Anxiety, PE, Fear)
 - Mechanical Ventilation
 - ↓ or Normal BP
 - Hypokalemia
 - Numbness & Tingling of Extremities
- 
- The diagram illustrates a person with respiratory alkalosis. The person's face shows signs of distress, including wide eyes and a slightly open mouth. Blue lightning bolt symbols around the head indicate symptoms like seizures or light-headedness. The lungs are shown in pink, with an upward arrow next to 'pH' and '(↑ 7.45)' and a downward arrow next to 'pCO₂' and '(35mm Hg)'. Below the lungs, an upward arrow is labeled '↑ Loss of CO₂ from Lungs'. Blue lightning bolt symbols are also placed near the chest area, suggesting symptoms like numbness or tingling.

RESPIRATORY ACIDOSIS

- Hypoventilation → Hypoxia

- Rapid, Shallow Respirations

- ↓ BP

- Skin/Mucosa Pale to Cyanotic

- Headache

- Hyperkalemia

- Dysrhythmias (↑K⁺)

I can't catch my breath.

- Drowsiness, Dizziness, Disorientation

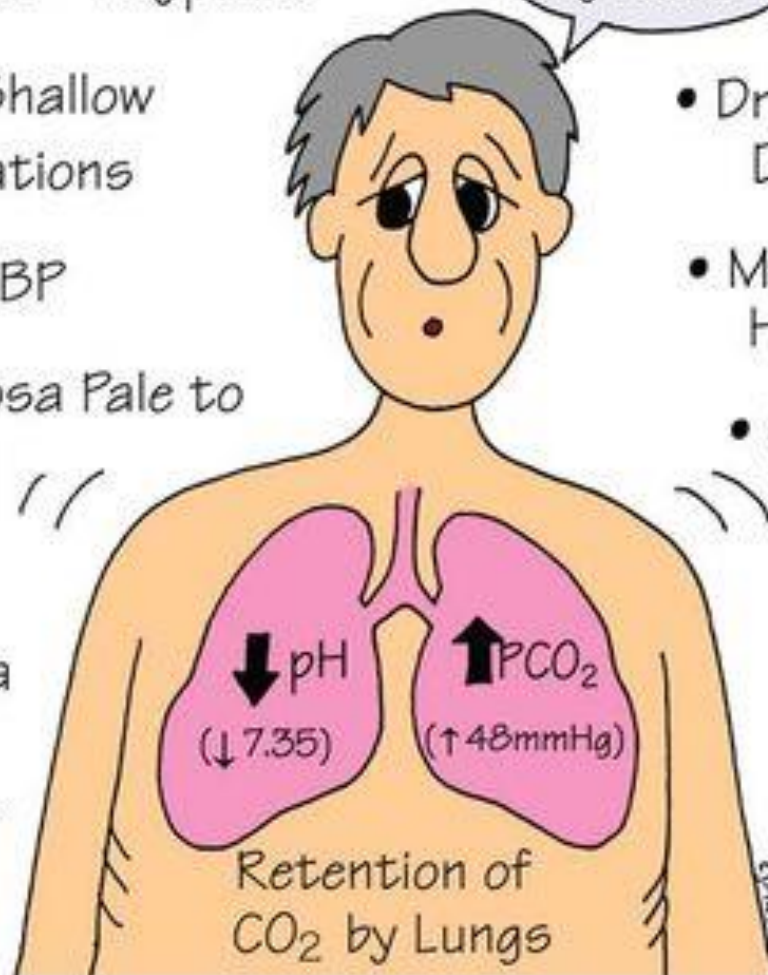
- Muscle Weakness, Hyperreflexia

- Causes:

- Respiratory Depression (Anesthesia, Overdose, ↑ICP)

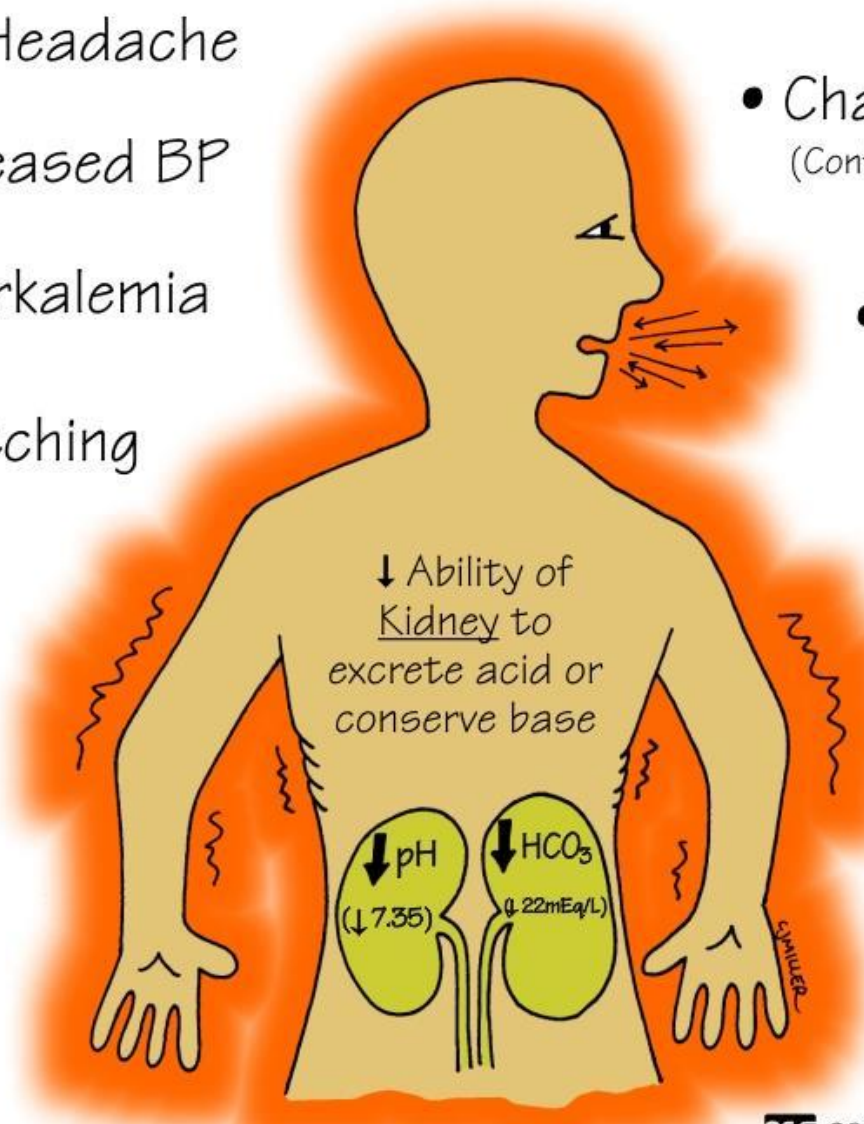
- Airway Obstruction

- ↓ Alveolar Capillary Diffusion (Pneumonia, COPD, ARDS, PE)



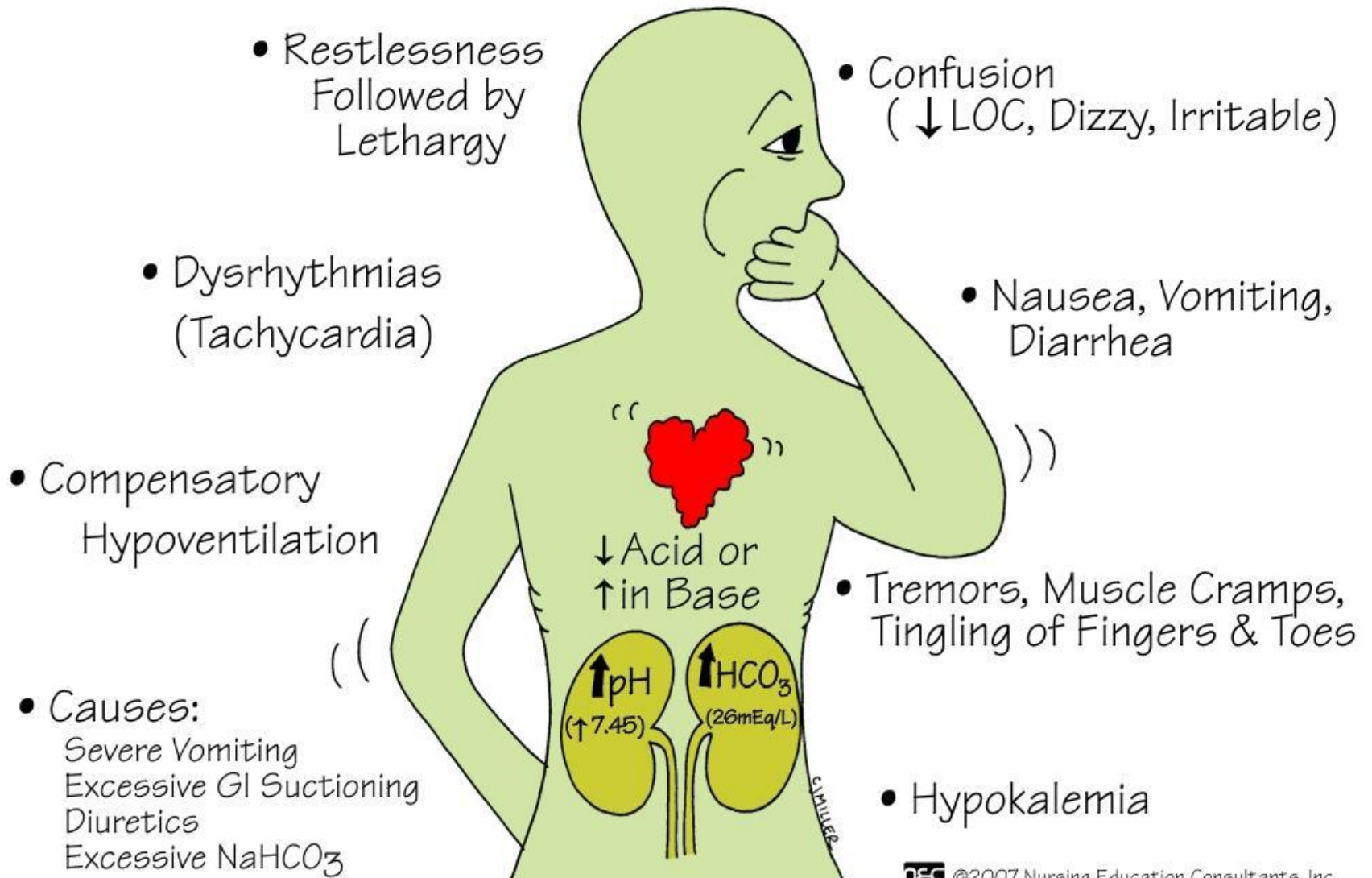
METABOLIC ACIDOSIS

- Headache
- Decreased BP
- Hyperkalemia
- Muscle Twitching
- Warm, Flushed Skin
(Vasodilation)
- Nausea, Vomiting, Diarrhea



- Changes in LOC
(Confusion, ↑ drowsiness)
- Kussmaul Respirations
(Compensatory Hyperventilation)
- Causes:
 - DKA
 - Severe Diarrhea
 - Renal Failure
 - Shock

METABOLIC ALKALOSIS



ACID BASE MNEMONIC (ROME)

R

Respiratory

Opposite

O

pH \uparrow PCO₂ \downarrow Alkalosis

pH \downarrow PCO₂ \uparrow Acidosis

M


Metabolic

Equal

E

pH \uparrow HCO₃ \uparrow Alkalosis

pH \downarrow HCO₃ \downarrow Acidosis



THORAX - Air in the pleural cavity, resulting in lung collapse...

- Dyspnea
- Anxiety
- Tachycardia
- Pleural Pain
- Asymmetrical Chest Wall Expansion
- ↓ Breath Sounds

* Causes *

Ruptured BLEB (COPD)

Thoracentesis

Trauma

Secondary Infection

* Diagnosed By: *

Chest X-Ray
ABG's

* Treatment: *

Chest Tube
Oxygen