

THE TELEFLEX
ACADEMY



MC-004183

Right Line, Right Now!

Ultrasound in Vascular Access

Teleflex[®]

Disclaimer

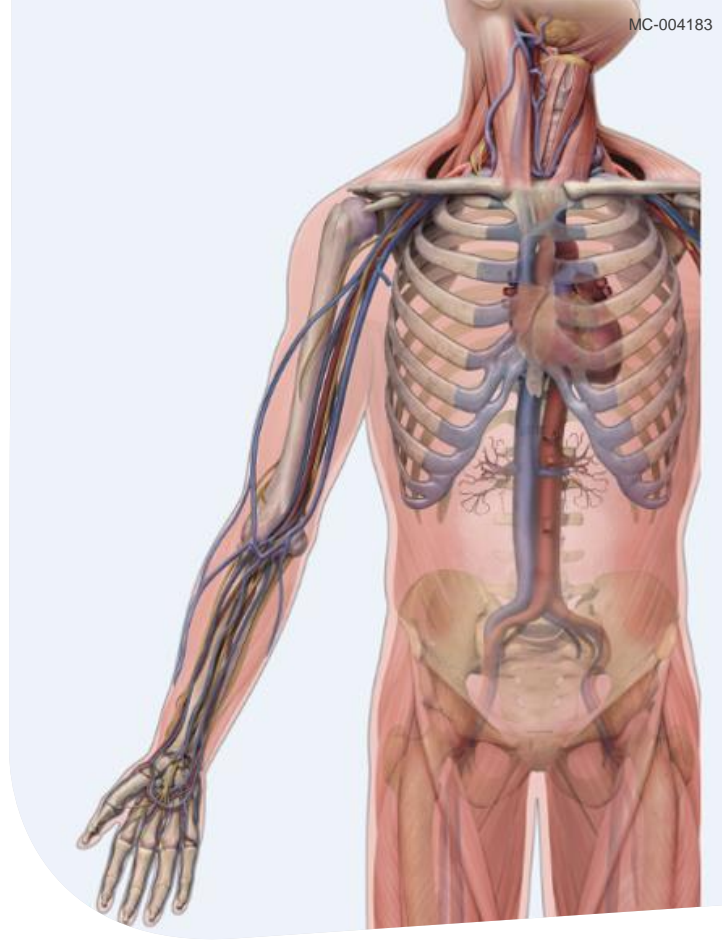
“This information is provided for clinical education purposes and is not intended to be a substitute for sound clinical judgment or decision making, or professional experience relative to diagnostic and treatment options of a specific patient's medical condition. Users should review the Instructions For Use for detailed information regarding the Instructions For Use, Contraindications, Potential Adverse Events, Warnings, and Cautions prior to using the device.”

Course Objectives

1. Discuss vascular access device selection for the right patient at the right time
2. Outline device options for vascular access in emergent, urgent, and medically necessary situations
3. Review anatomical characteristics and locations for device insertion, nerve, artery, and vein structures
4. Review guidelines for ultrasound use during vascular access procedures

Emergent Vascular Access

***Right Line,
Right Patient,
Right Time***

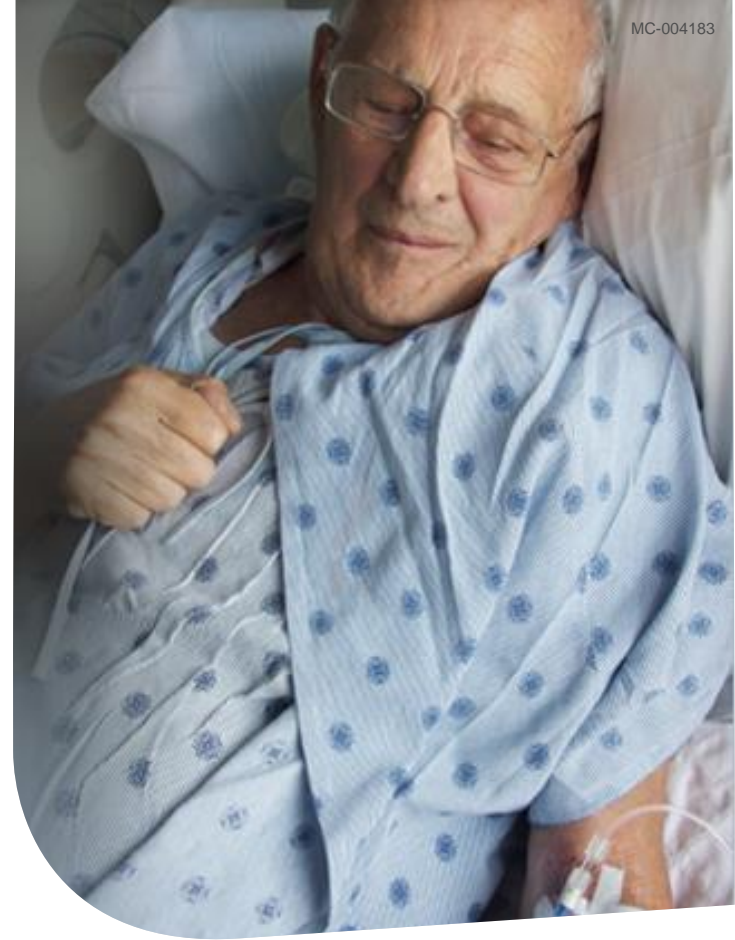

Right Line¹

- Educate and train all staff involved in vascular access practices¹
- Selection of the device that is most appropriate for therapy and preserves vessel health
- Insert the smallest device with the least amount of lumens required for therapy¹
- Insert the appropriate device using evidence-based guidelines

Right Patient

- Evaluation of patient risk factors and need
 - Acute
 - Chronic
- Previous Medical History
- Patient Assessment
 - Assessment of vascular anatomy
 - Laboratory values
- Exit site considerations
- Risk/Benefit
- Therapy
- Unit outcomes²



Right Time^{1,5}

- Insertion of device in a timely manner to avoid delay in treatment
- Daily assessment and goals for device necessity
- Prompt removal of the device when no longer used

General Recommendations

The goals of the device selection process are to use the least invasive device with the lowest risk of complications and to use a device that will last for the duration of the therapy or one that may be managed with minimal replacement.

- The Vascular Access Device (VAD) selected is of the smallest outer diameter with the fewest number of lumens and is the least invasive device for the prescribed therapy ¹
- Use a single lumen catheter unless multiple ports are essential for the management of the patient ²
- “Choice of the smallest gauge possible, ideally with a catheter-to-vein ratio of 45% (thrombosis prevention) ^{3,5}

General Recommendations

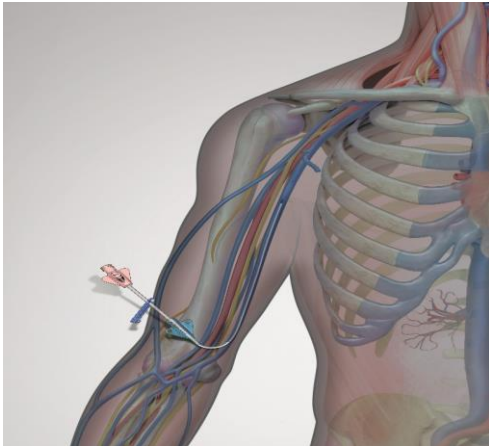
The vascular device assessment is not a static process; it is a dynamic process which requires the frequent reassessment of the patient as needs may suddenly change.¹

- Complete the daily re-assessment of the line to determine IV device necessity¹
- Short-term peripheral catheters that need to be in place for > 5 days should not be routinely changed if no evidence of infection is observed²
- Prompt removal of the IV device when no longer needed²

Peripheral vs. Central Lines: Definition

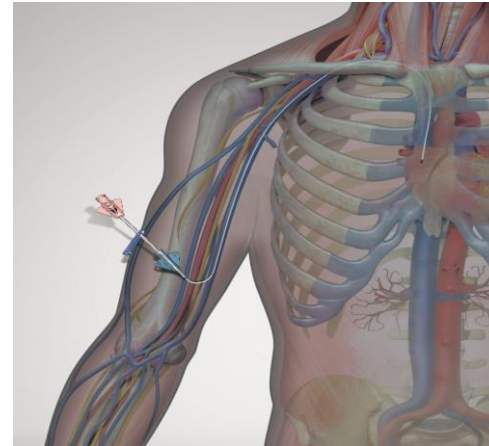
Peripheral Vascular Access Device:

- Catheter tip located in peripheral vein

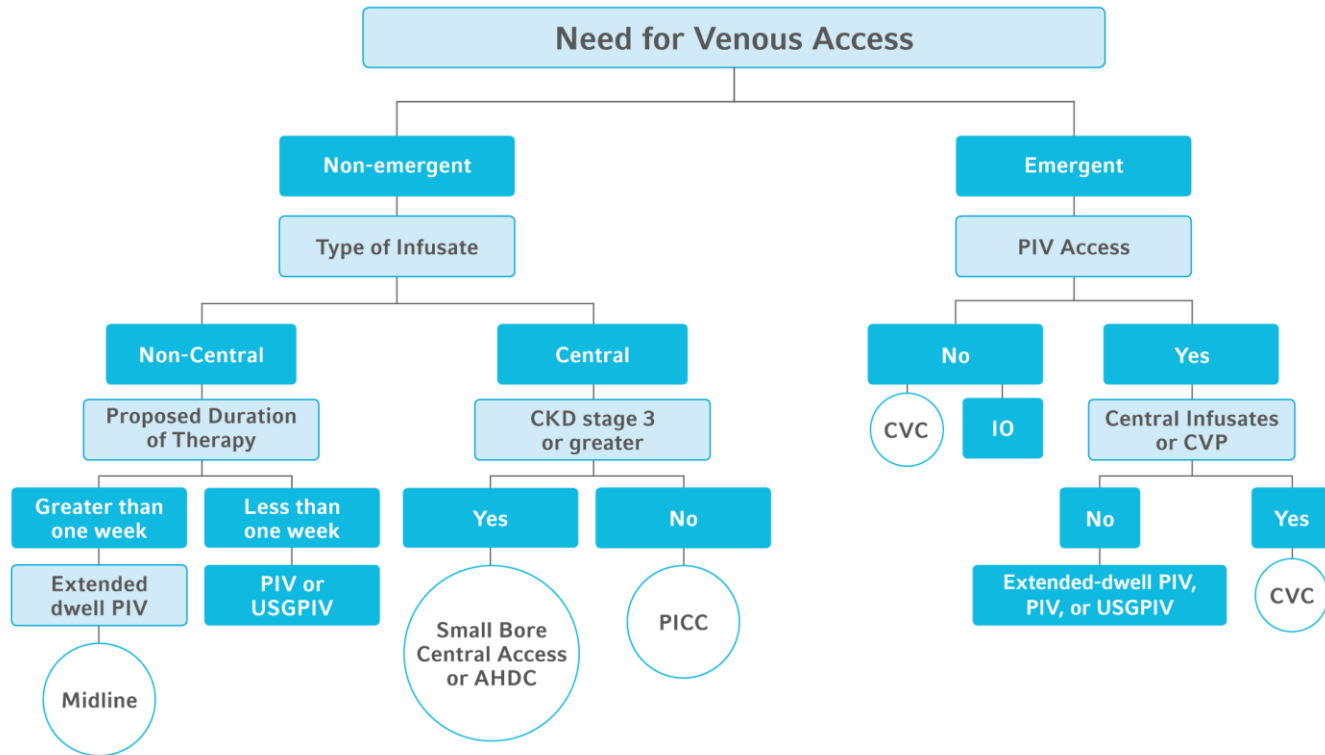


Central Venous Access Device (CVAD):

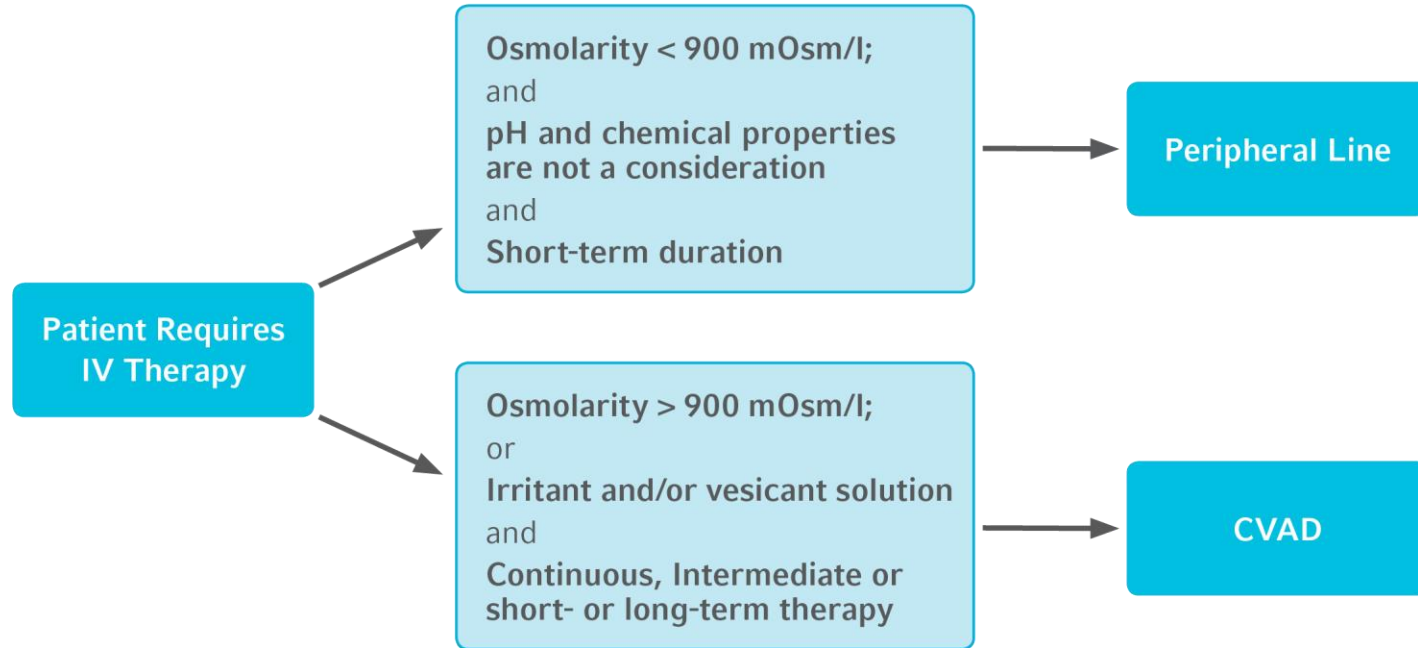
- Catheter tip located in the lower third of superior vena cava at or above the cavoatrial junction



Protected Technology Device Selection⁵



Peripheral vs. Central Line



We Should Not Persist With “Default” Option

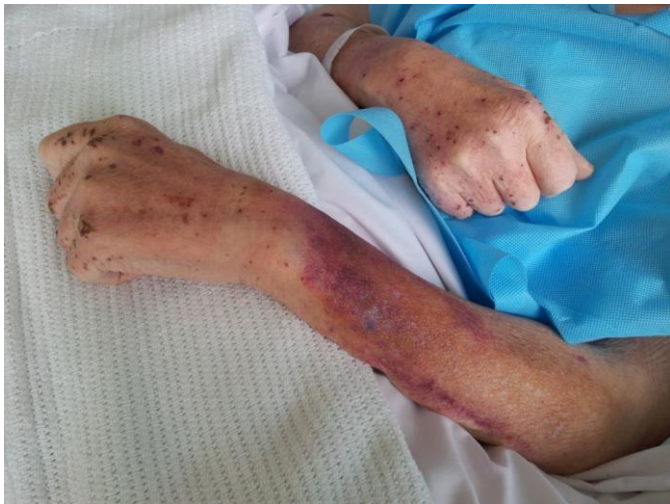
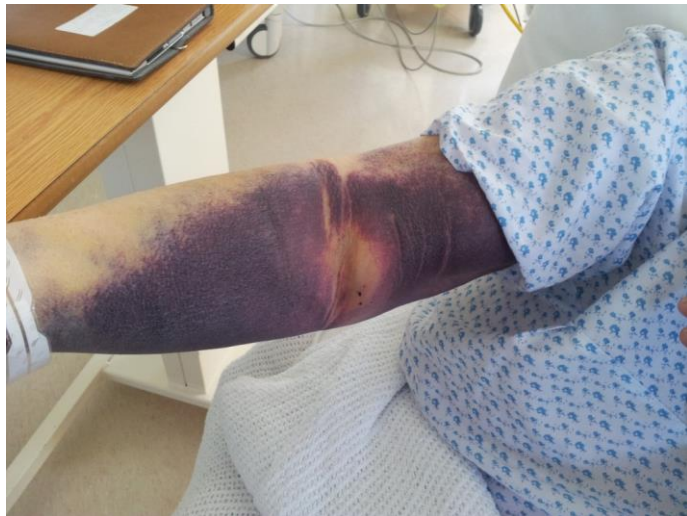
Photo Courtesy Tim Jackson, MD. Used with permission.



We Should Not Persist With “Default” Option

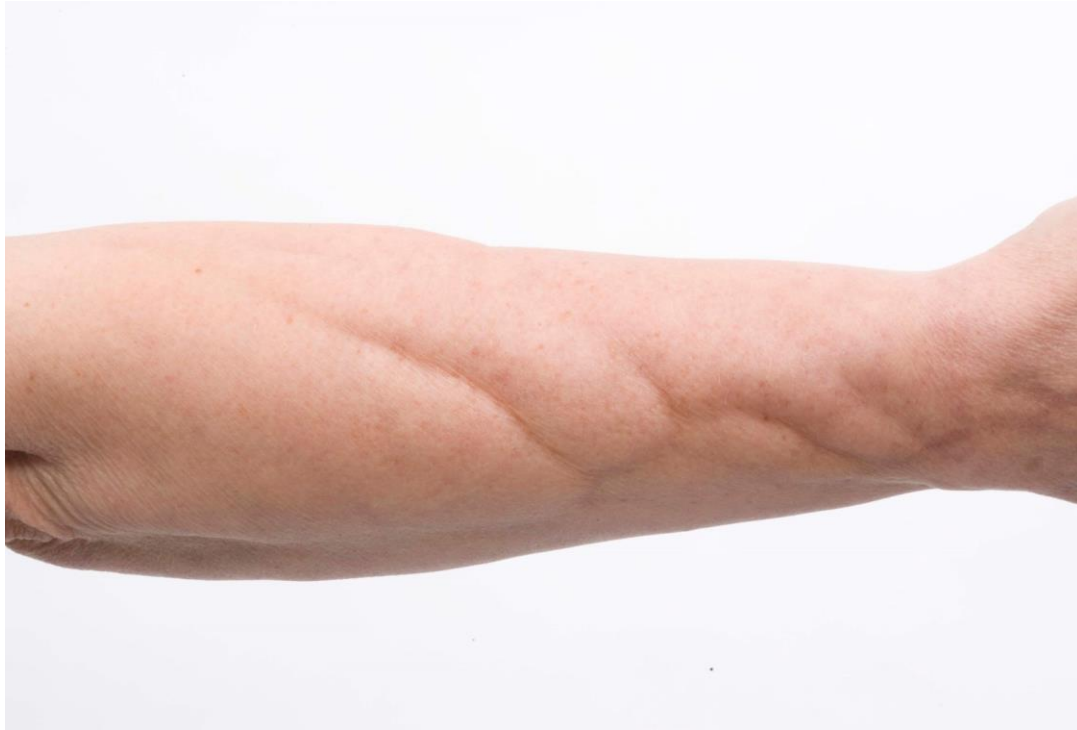

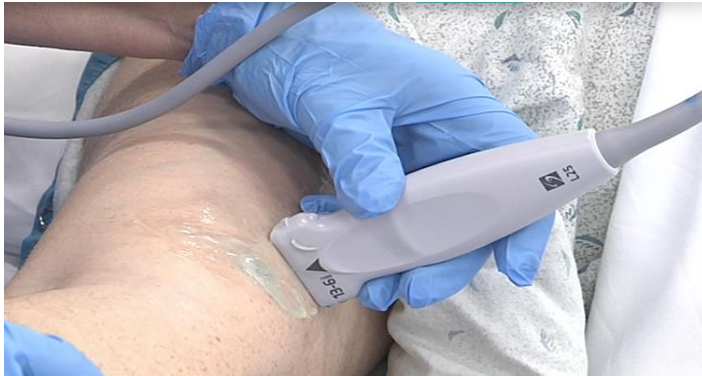Photo Courtesy Steven Hill. Used with permission.

Ultrasound-Guided Venous Access

Benefits of Ultrasound

Ultrasound reduces insertion risks by allowing:

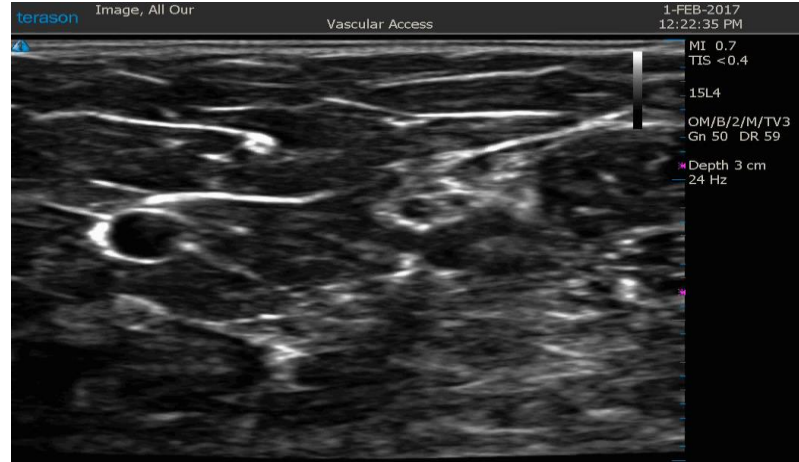- Clear visualization of veins during access
- Assessment of vein diameter to determine vein to catheter ratio
- Assessment of vessel health to include blood flow and compressibility
- Location of the best site for venipuncture
- Identification of potentially problematic anatomic issues and venous anomalies that may contraindicate site selection



Identifying differences of veins and arteries

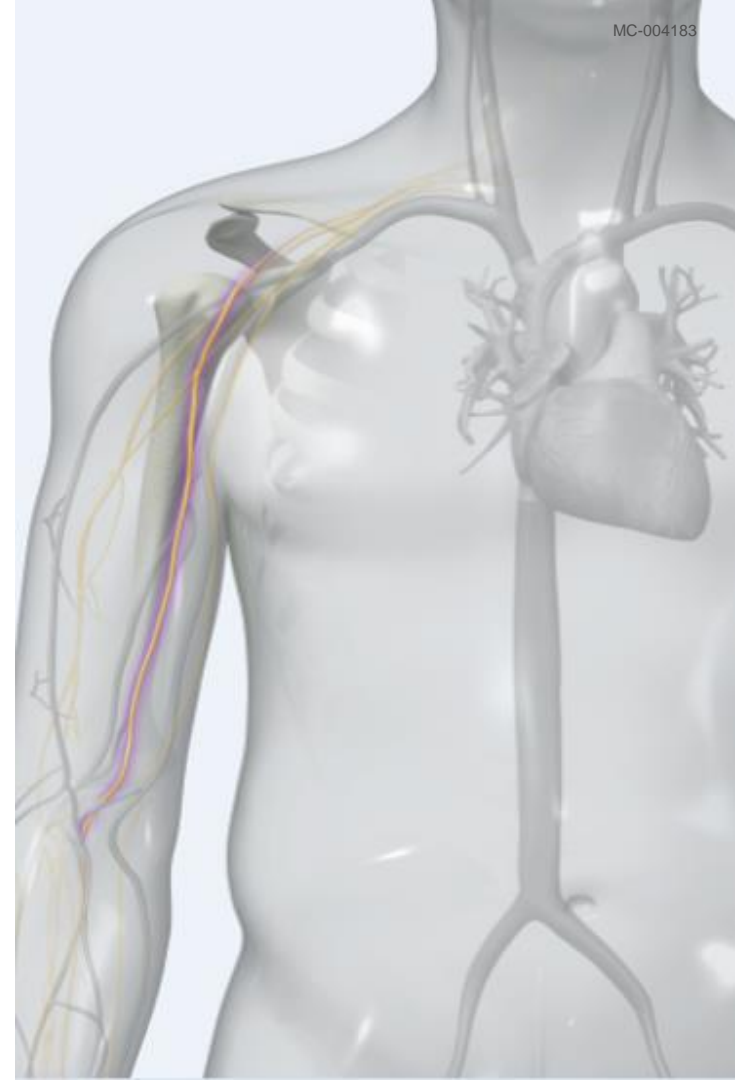
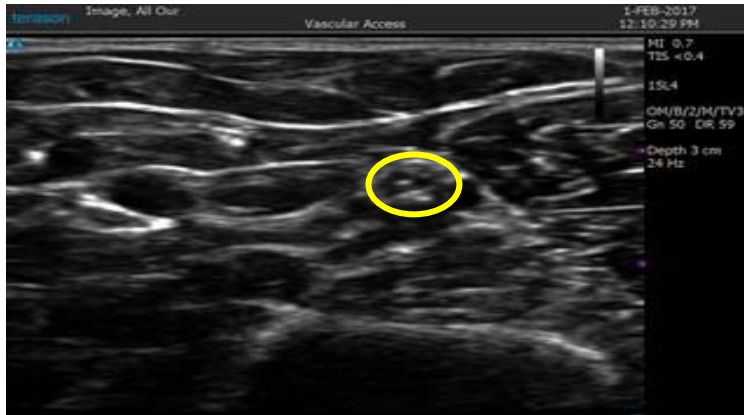Both circular black structures

- Veins:
 - Easily compressible
 - Should not be pulsatile
 - Thinner walls
- Arteries:
 - Pulsate
 - Difficult to compress
 - Arterial walls appear thicker



Nerves

- Lies near the brachial artery
- Appears as “cauliflower” bundle near the brachial artery
- Identify nerves prior to cannulation
- Assess for post insertion pain



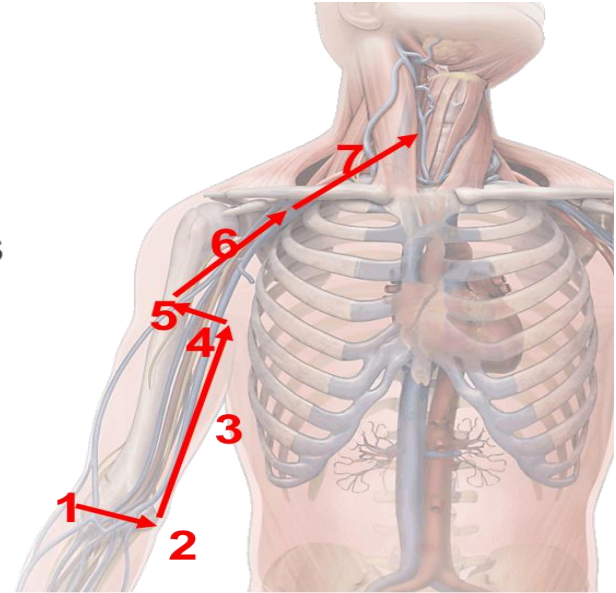
Rapid Assessment of Peripheral Venous Anatomy

Prior to insertion identify:

- Vein patency
- Appropriate size/depth of vessel
- Pathway and blood flow in vessel
- Catheter length to tissue depth proportion
- Location of surrounding anatomical structures

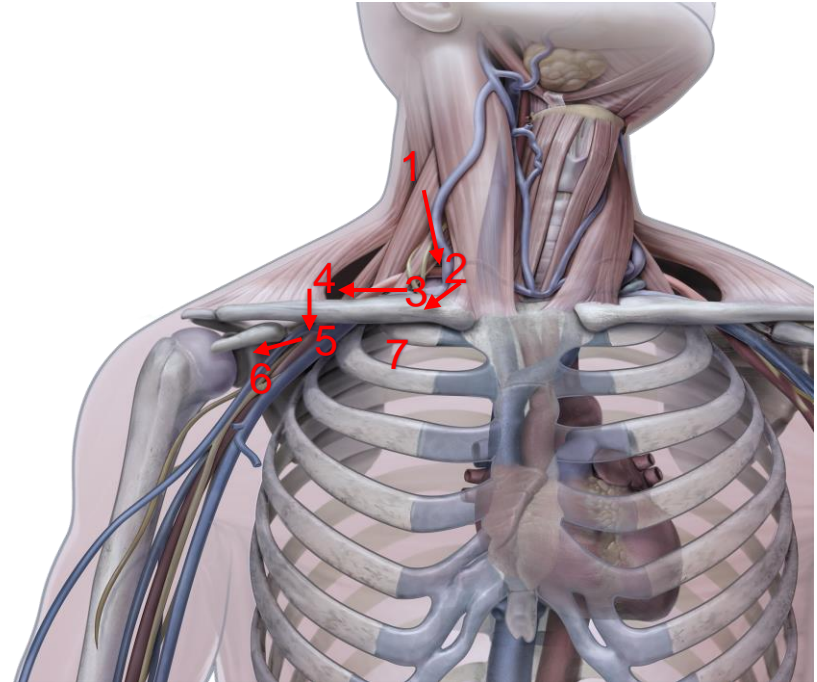
After insertion recognize:

- Continued patency of vein
- Catheter related vessel thrombosis

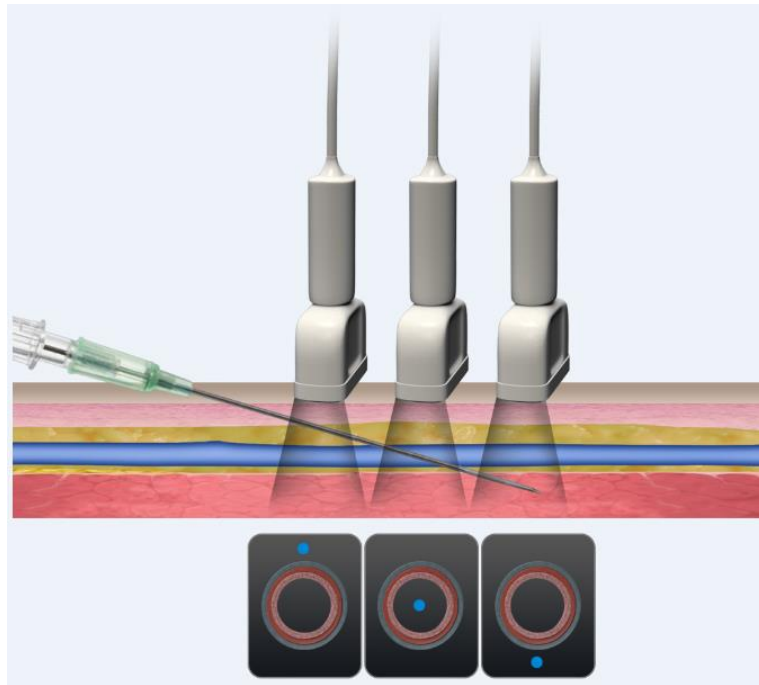


Rapid Assessment of Central Venous Anatomy

- The RaCeVA Protocol allows for a systematic approach for rapid assessment of the central veins using ultrasound guidance, not only to exclude venous abnormalities such as:
 - Thrombosis
 - External compression
 - Anatomical variation of size and shape
- But also aids the clinician in a full evaluation for optimum site selection and to choose the best approach.



Visualizing the Needle



References

1. Gorski LA, Hadaway L, Hagle M, McGoldrick M, Orr M, Doellman D. Infusion therapy standards of practice. *Journal of Infusion Nursing*. 2016;39(1Supplement):S1–S159.
2. Phillips L, Brown L, Campbell T, Miller J, Proehl J, Youngberg B. Recommendations for the Use of Intraosseous Vascular Access for Emergent and Nonemergent Situations in Various Health Care Settings: A Consensus Paper. *Journal of Infusion Nursing*, November/December 2010; 33(6):346-351.
3. Emergency Nursing Resource: Difficult Intravenous Access. ENA; December 2012.
4. Leidel BA, Kirchoff C, Bogner V, Braunstein V, Biberthaler P, Kanz K-G. Comparison of intraosseous versus central venous vascular access in adults under resuscitation in the emergency department with inaccessible peripheral veins. *Resuscitation*. 2012;83(1):40-45.
5. *Infection Control and Hospital Epidemiology*, Vol. 35, No. 7 (July 2014), pp. 753-771.
6. American Association of Critical-Care Nurses. American Association of Critical-Care Nurses endorses nurses' expanded role in use of IO access devices. <http://www.aacn.org/WD/PressRoom>. Published June 21, 2010. Accessed March 21, 2017.
7. Hoskins SL, Kramer GC, Stephens CT, Zachariah BS. Efficacy of epinephrine delivery via the intraosseous humeral head route during CPR. *Circulation* 2006;114:II_1204.
8. Hoskins SL, Zachariah BS, Copper N, Kramer GC. Comparison of intraosseous proximal humerus and sternal routes for drug delivery during PR. *Circulation* 2007;116:II_933.
9. Horton MA, Beamer C. Powered intraosseous insertion provides safe and effective vascular access for pediatric emergency patients. *Pediatric Emergency Care* 2008;24(6):347-50.
10. Truemper EJ, Beamer CL, Miller LJ, et al. Distal Femur site Is a viable option for IO vascular access in pediatric patients. *Ann Emerg Med* 2012;60(4):S90. Research sponsored by Teleflex Incorporated.
11. Puga T, Montez D, Philbeck T, Davlantes C. Adequacy of intraosseous vascular insertion sites for high-volume fluid infusions (abstract 263). *Crit Care Med* 2016;44(suppl 12).
12. Vidacare Internal Studies (2013); data on file. Average time for medication infusion from humerus to the right atrium with use of the Arrow® EZ-IO® Vascular Access System in healthy adult; individual results may vary.
13. Philbeck TE, Miller LJ, Montez D, Puga T. Hurt so good; easing IO pain and pressure. *JEMS* 2010;35(9):58-69.

References

14. Dolister M, Miller S, Borrón S, et al. Intraosseous vascular access is safe, effective and costs less than central venous catheters for patients in the hospital setting. *J Vasc Access* 2013;14(3):216-24. doi:10.5301/jva.5000130.
15. Chreiman, K.M., et al. (2018). The IOs have it: a prospective observational study of vascular access success rates in patients in extremis using video review. *Journal of Trauma and Acute Care Surgery*, Publish Ahead of Print DOI: 10.1097/TA.0000000000001795
16. Wampler D, Schwartz D, Shumaker J, et al. Paramedics successfully perform humeral EZ-IO® intraosseous access in adult out-of-hospital cardiac arrest patients. *Am J Emerg Med* 2010;56(3):S88.VS doi.org/10.1016/j.ajem.2011.07.010.
17. Miller L, Philbeck T, Montez D, Puga T. A two-phase study of fluid administration measurement during intraosseous infusion. *Ann Emerg Med* 010;56(3):S151.
18. Ong MEH, Chan YH, Oh JJ, Ngo AS-Y. An observational, prospective study comparing tibial and humeral intraosseous access using the EZ-IO®. *Amer J Emerg Med* 2009;27:8.
19. Paxton JH, Knuth TE, Klausner HA. Proximal humerus intraosseous infusion: a preferred emergency venous access. *The J Trauma* 2009;67(3):606-11.
20. Montez DF, Puga T, Miller L, Saussy J, Davlantes C, Kim S, Philbeck T. Intraosseous Infusions from the Proximal Humerus Reach the Heart in Less Than 3 Seconds in Human VoKovar J, Gillum L. Alternate route: the humerus bone—a viable option for IO access. *JEMS* 2010;35(8):52-9.
21. Teleflex Internal Data on File 2018
22. Davidoff J, Fowler R, Gordon D, Klein G, Kovar J, Lozano M, Potkya J, Racht E, Saussy J, Swanson E, Yamada R, Miller L. Clinical evaluation of a novel intraosseous device for adults: prospective, 250-patient, multi-center trial. *JEMS* 2005;30(10):s20-3. Research sponsored by Teleflex Incorporated
23. Cooper BR, Mahoney PF, Hodgetts TJ, Mellor A. Intra-osseous access (EZ-IO) for resuscitation: UK military combat experience. *J R Army Med Corps*. 2007;153(4):314-316

THE TELEFLEX
ACADEMY

Thank You

Thank You