



ABC INTERPRETATION OF CHEST X RAYS.

www.criticalcarepractitioner.co.uk



TECHNICALS

AIRWAY

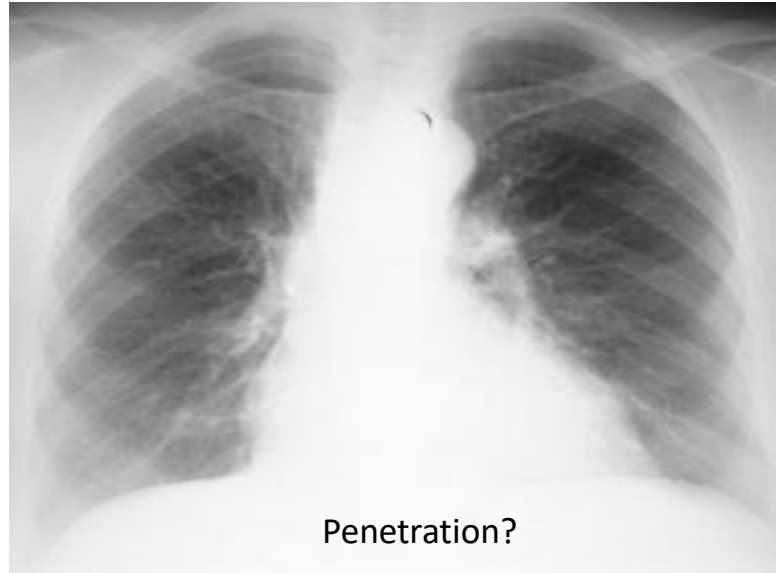
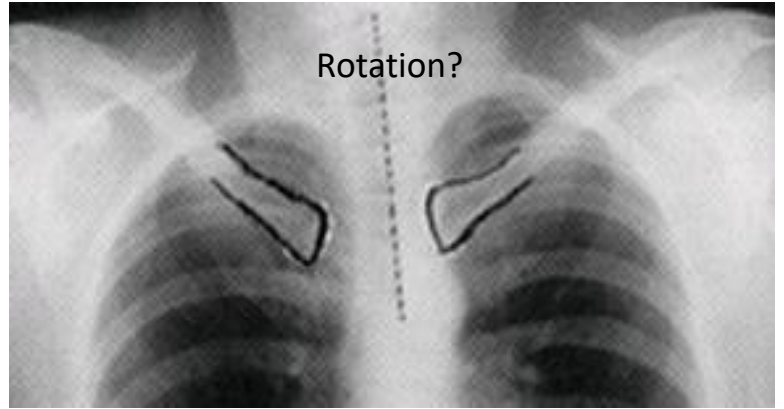
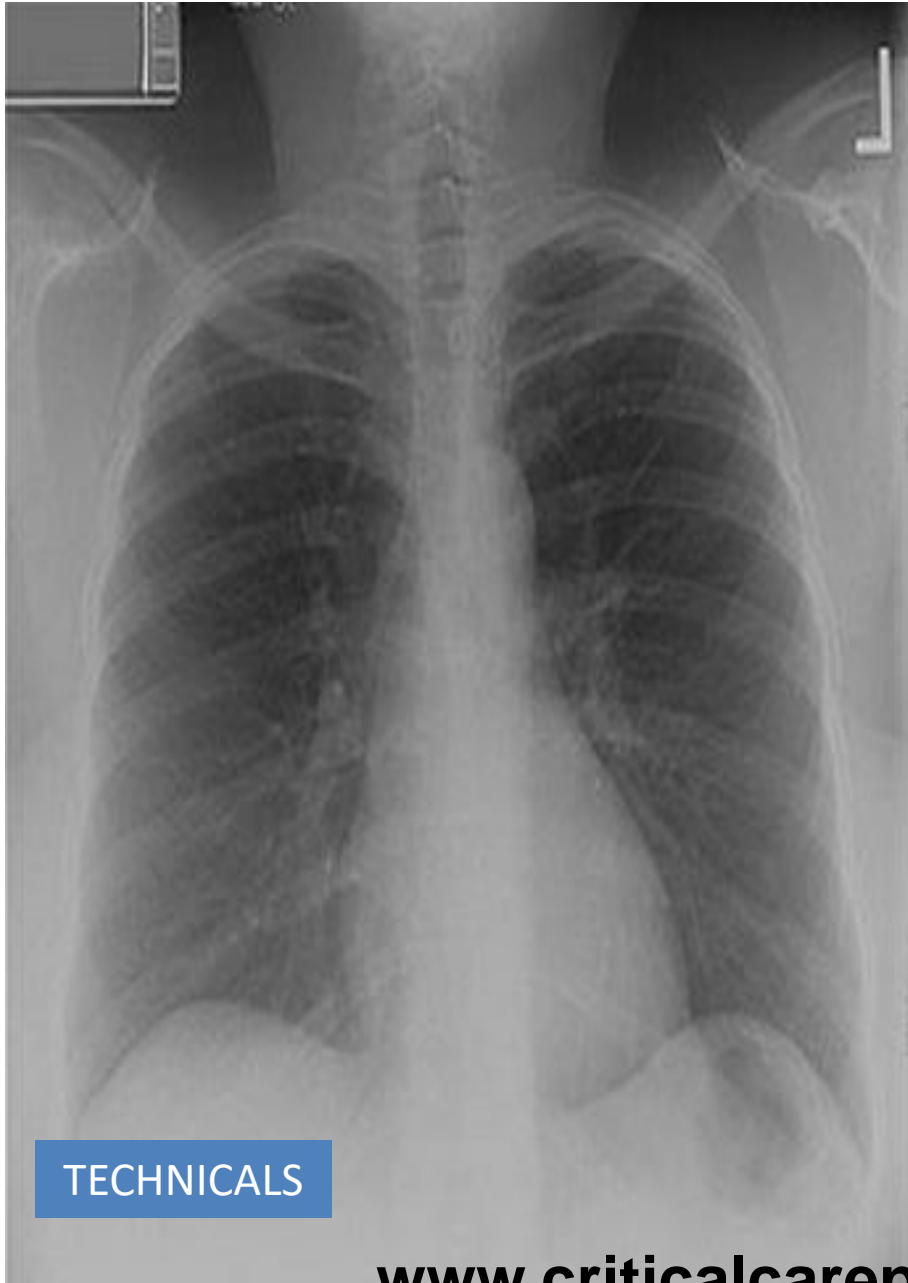BONES

CARDIAC

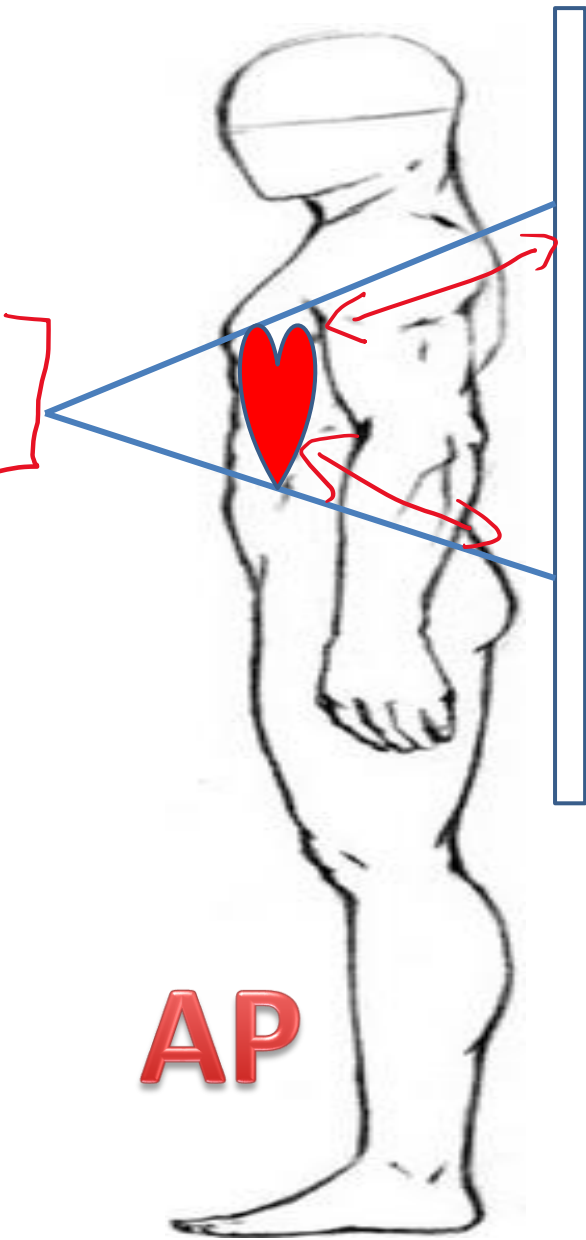
DIAPHRAGM

EQUAL LUNG **F**IELDS

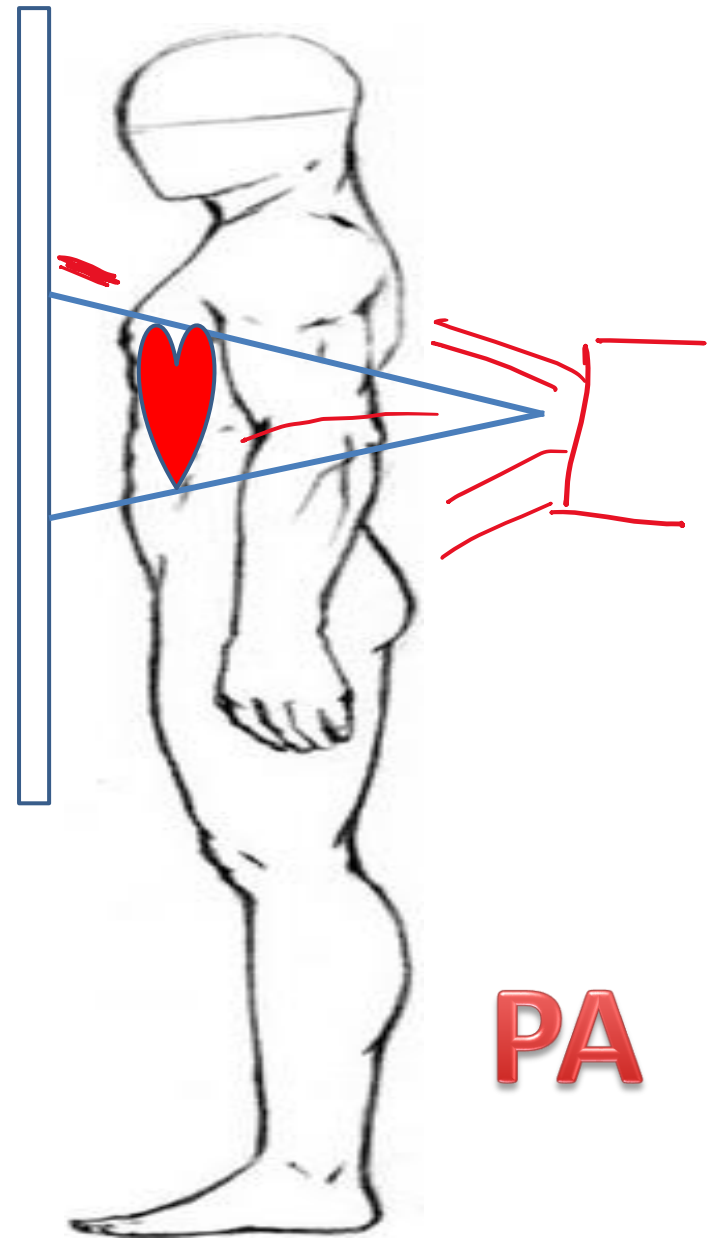
GASTRIC **B**BUBBLE



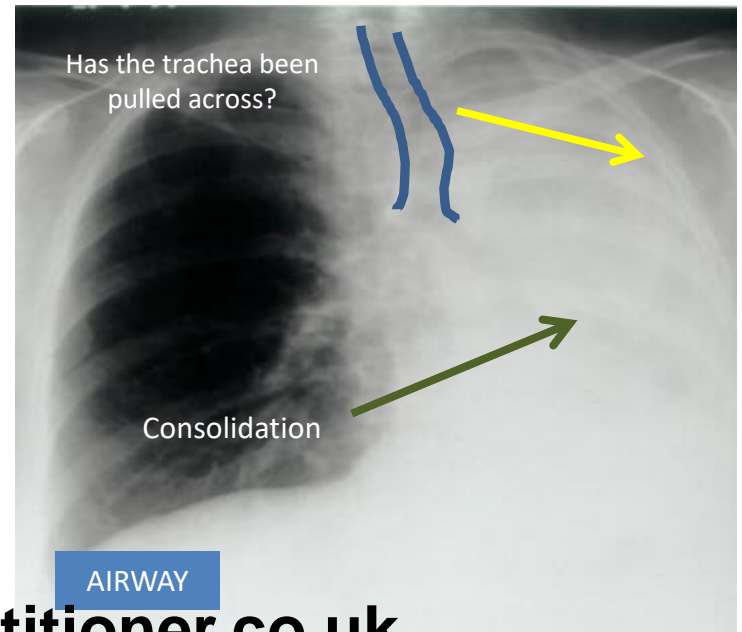
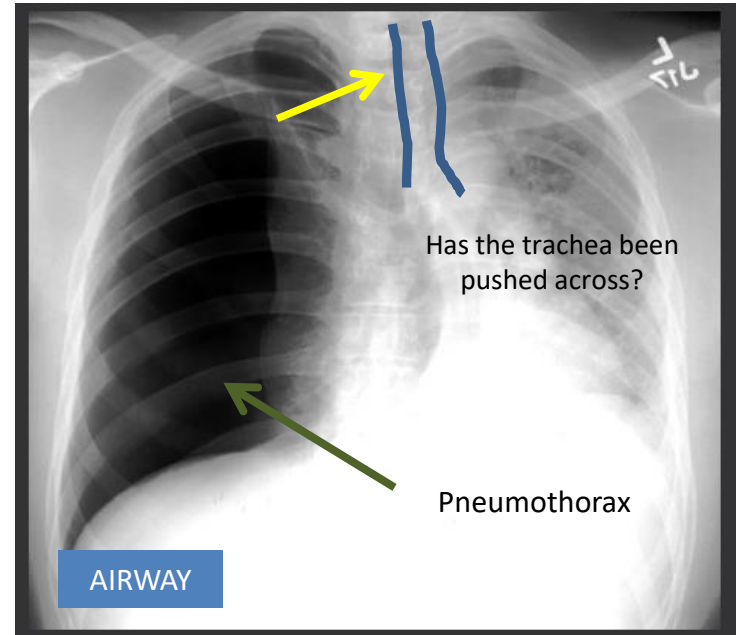
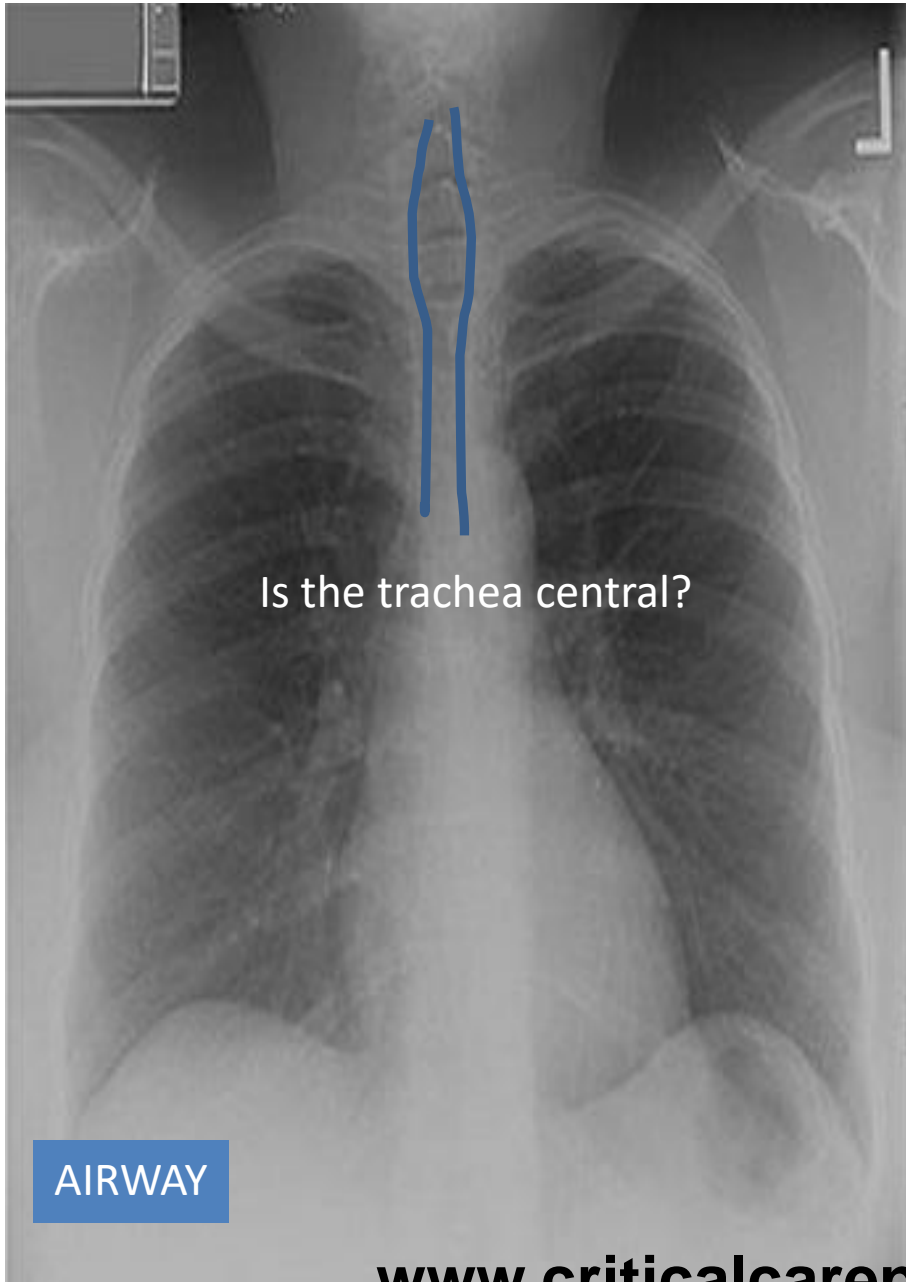
PA or AP?

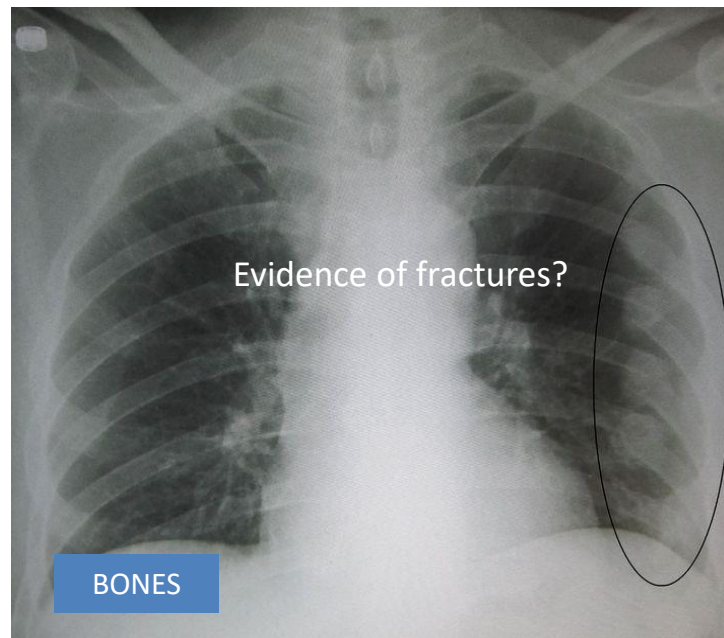
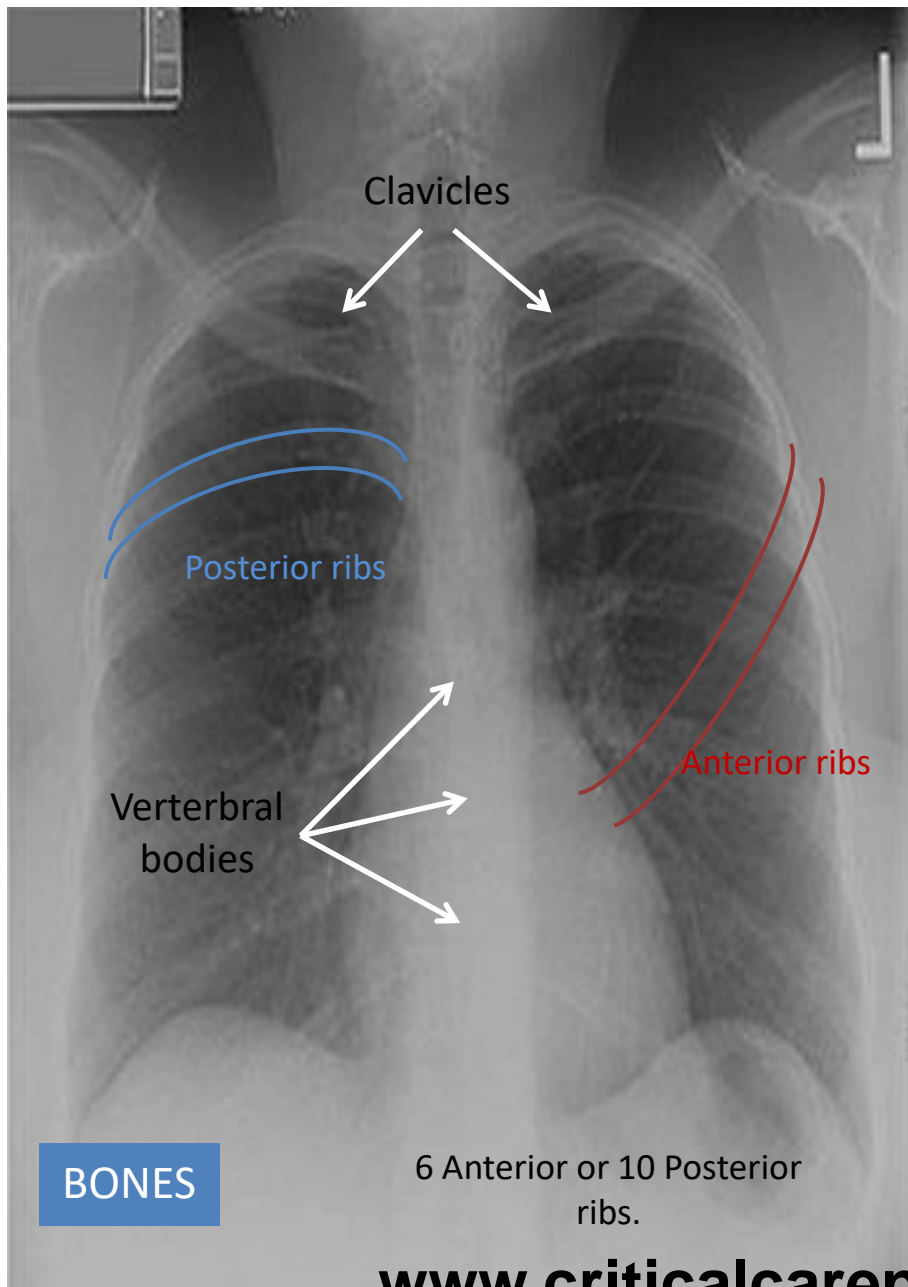


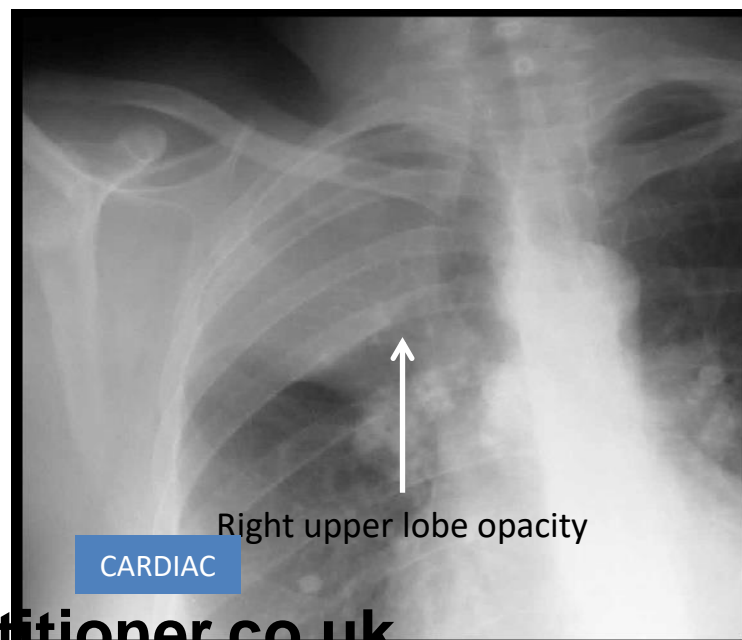
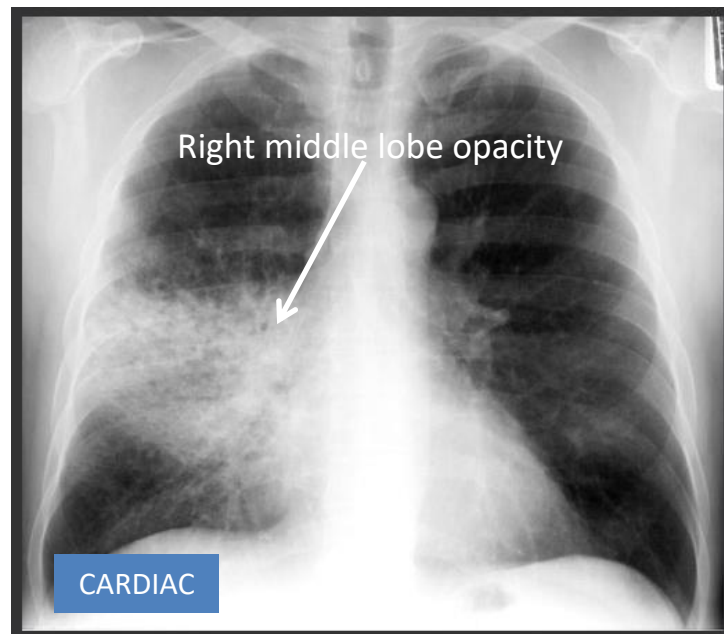
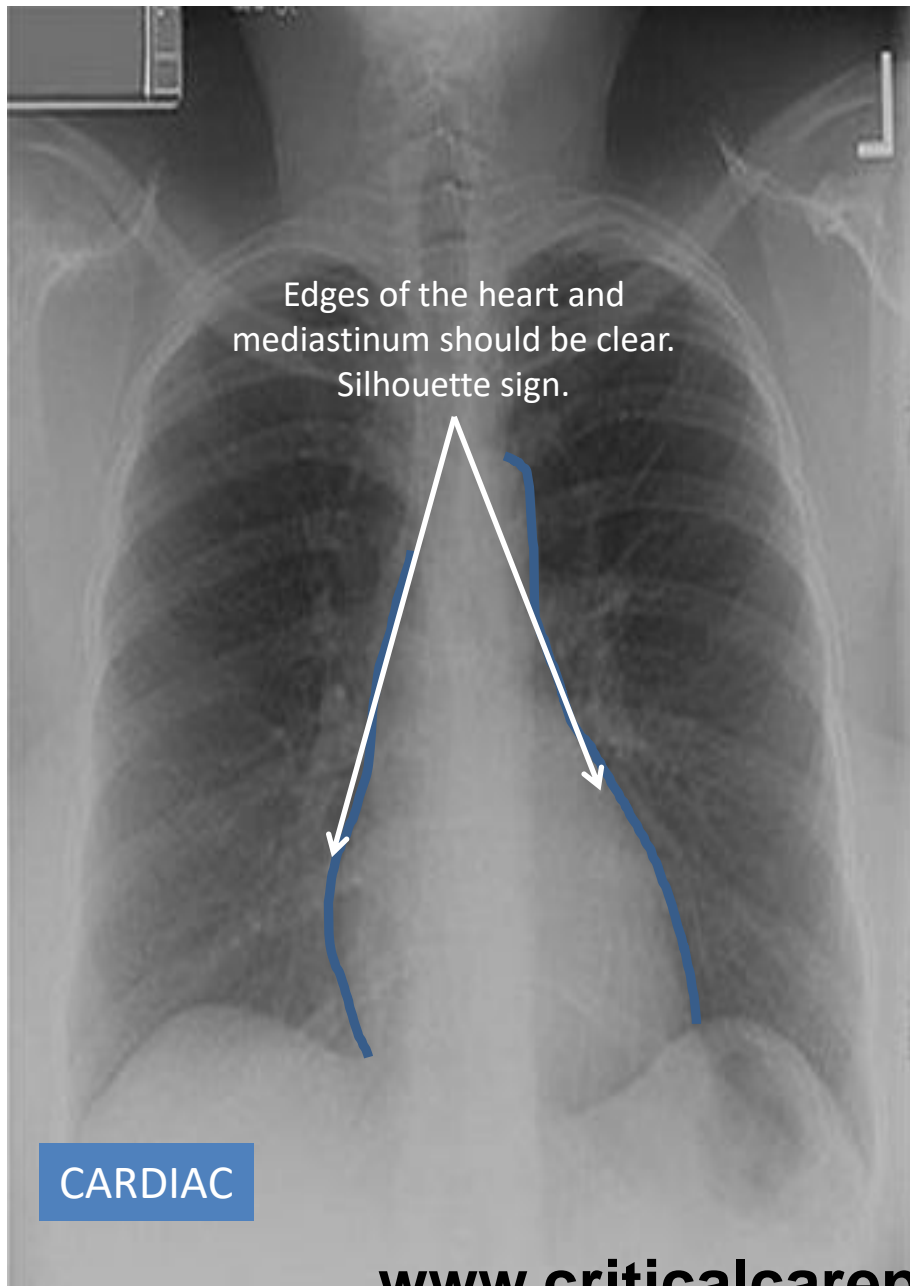
AP

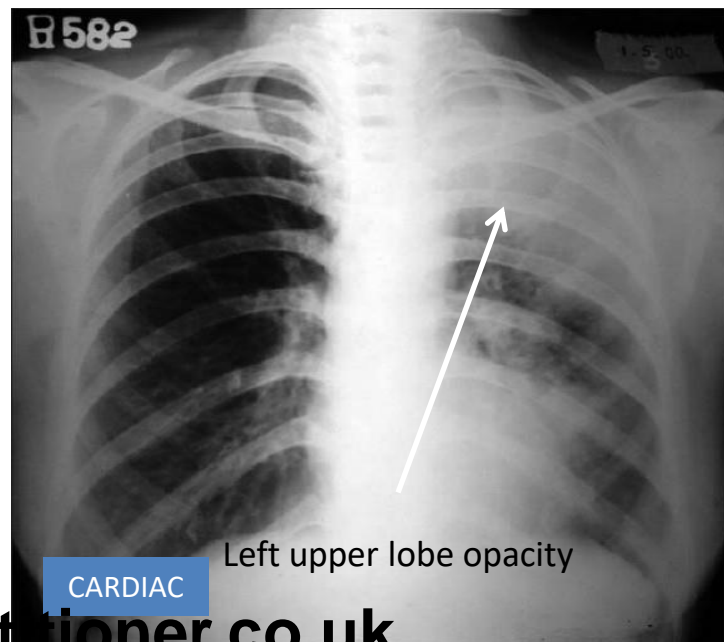
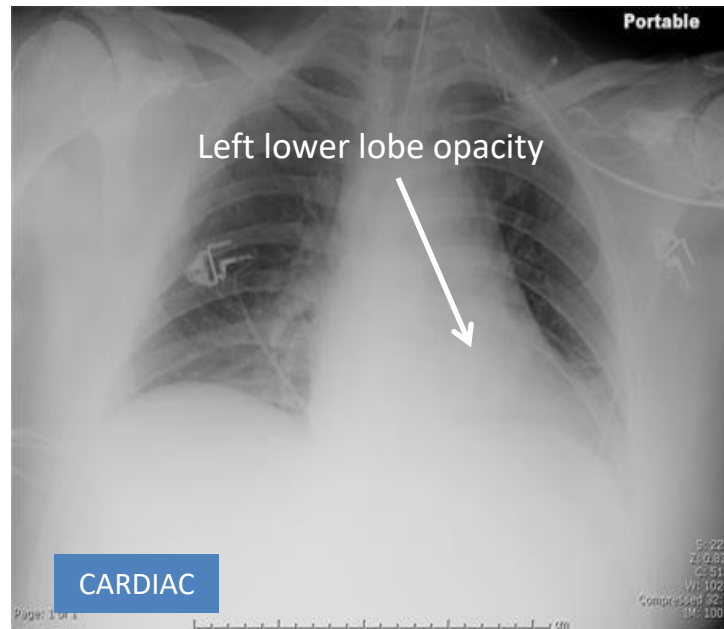
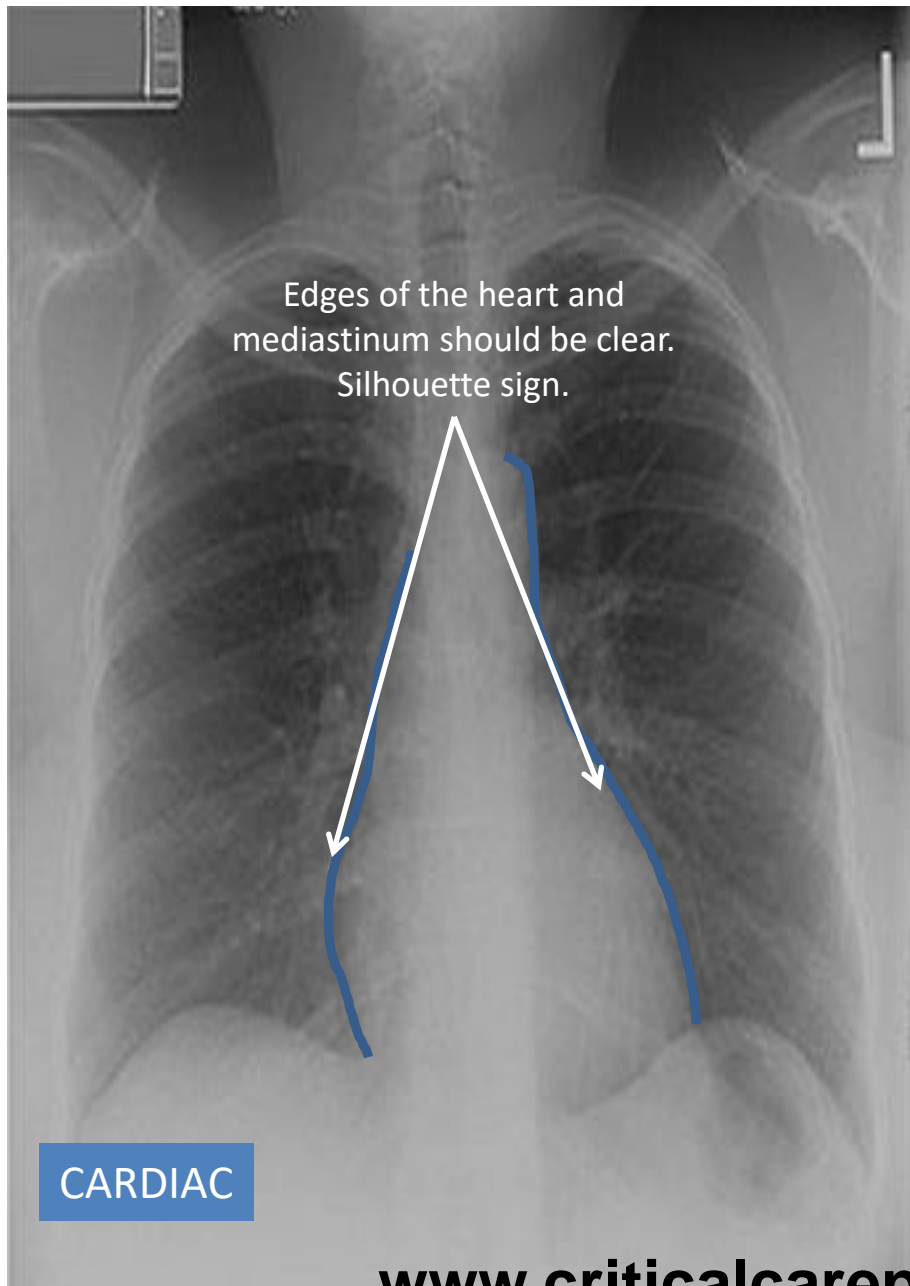


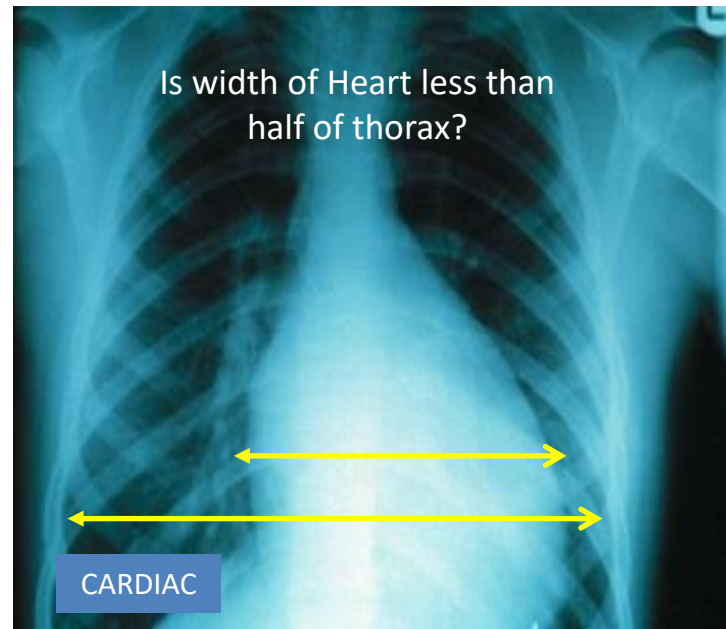
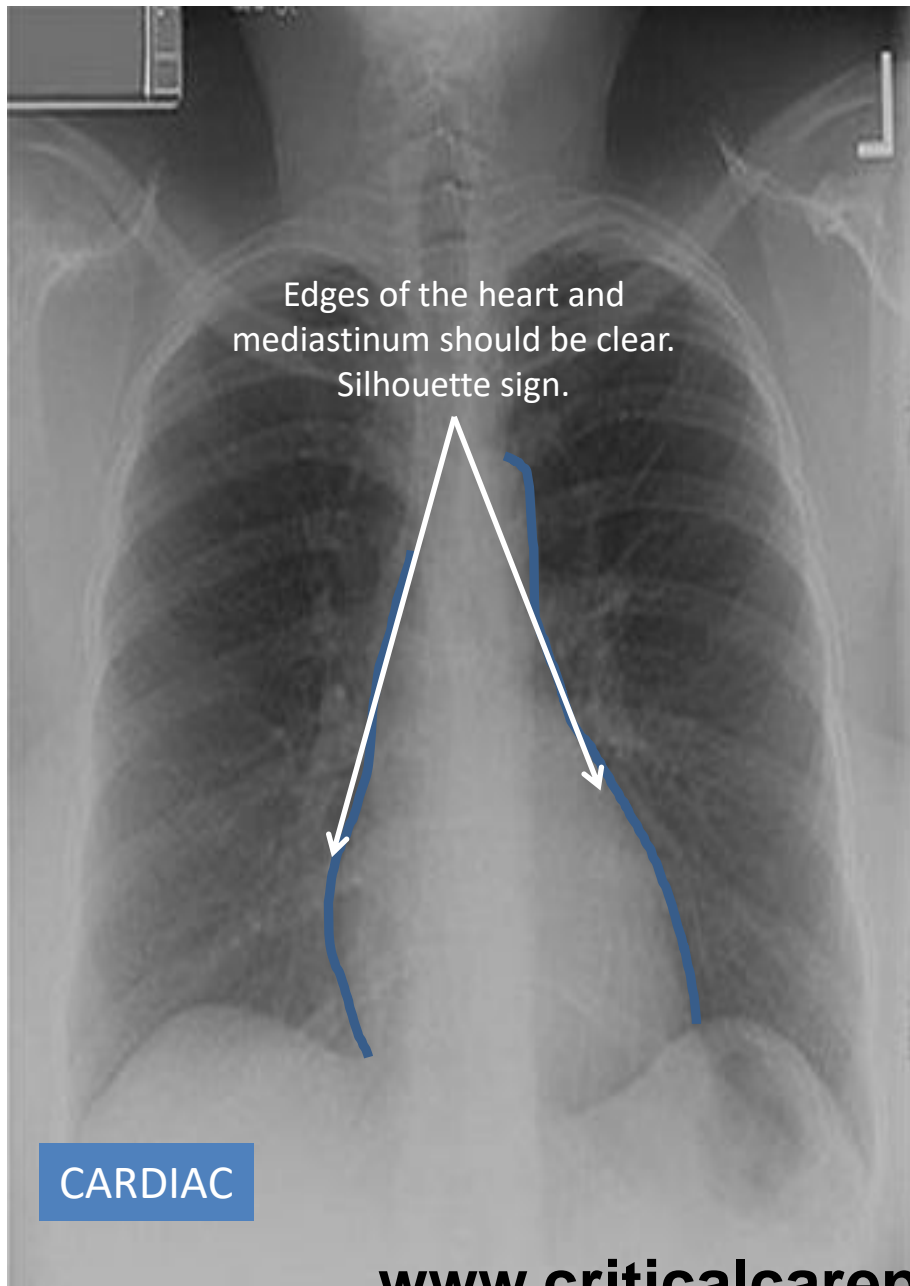
PA

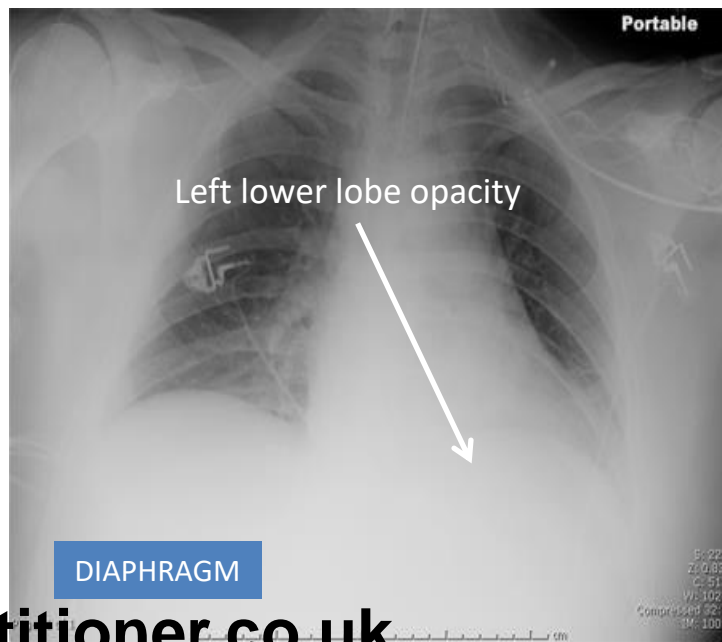
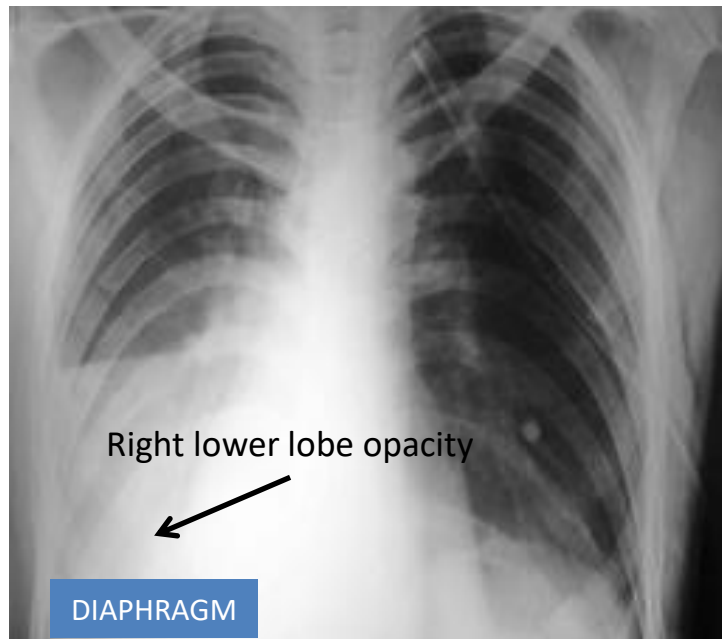
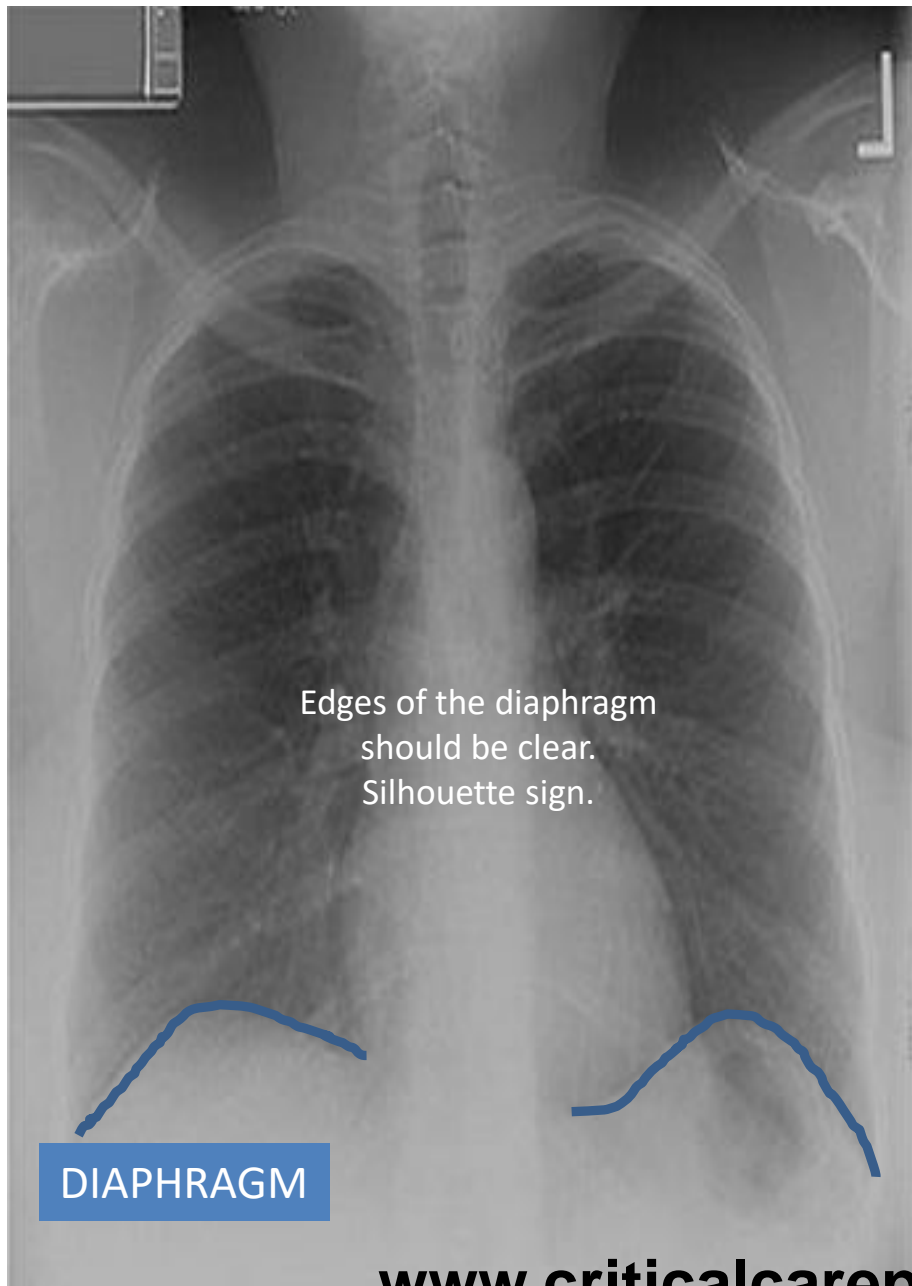


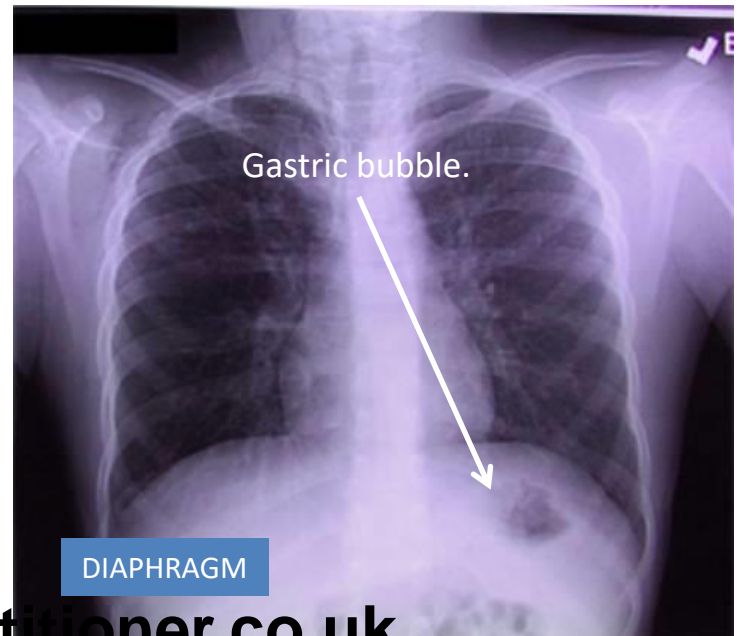
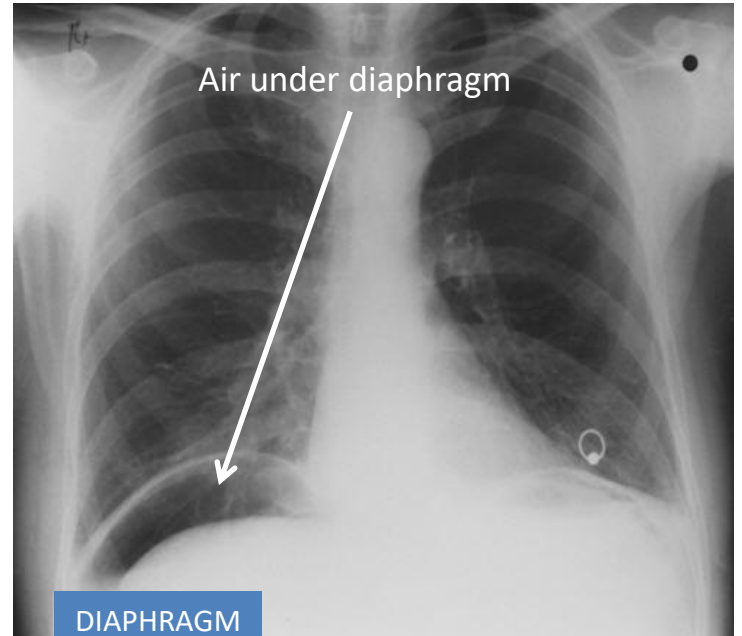
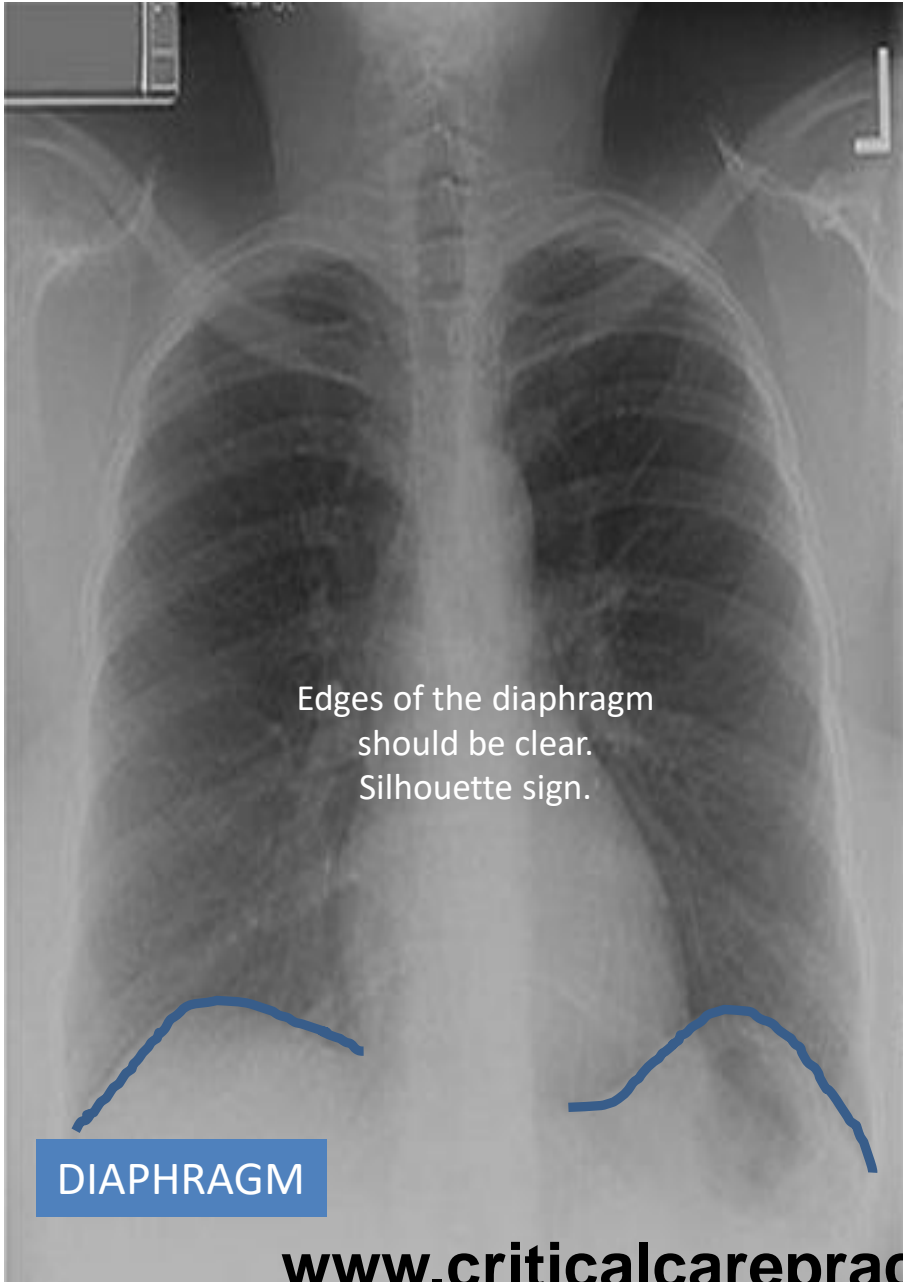


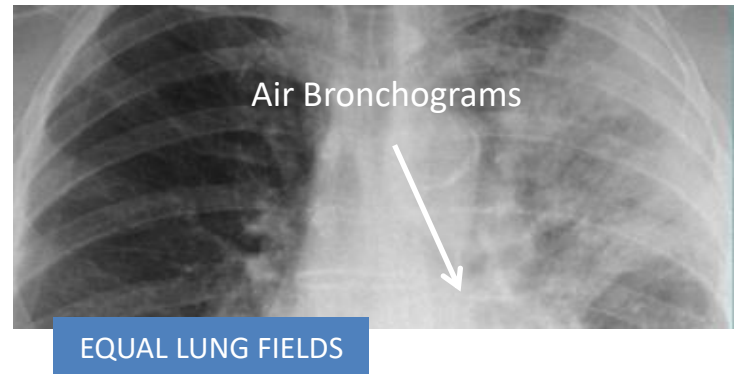
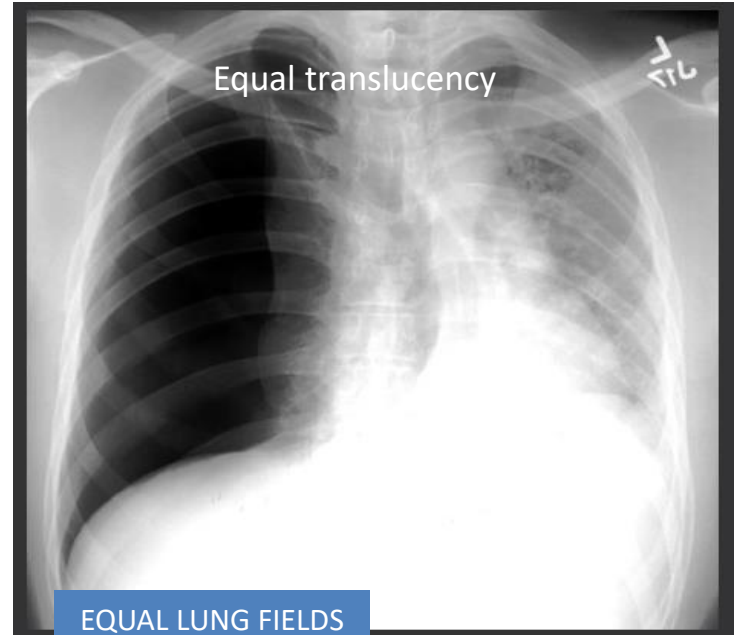
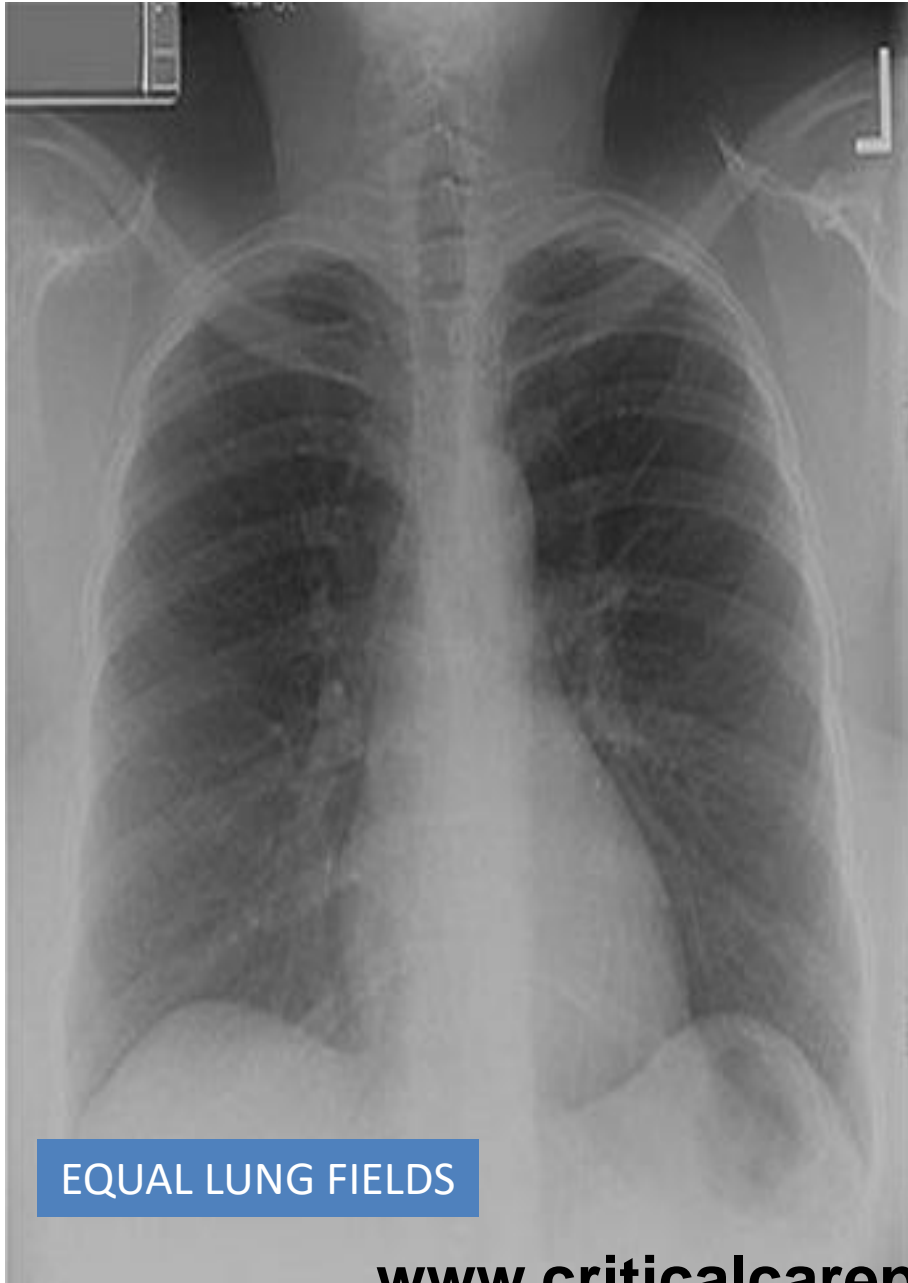

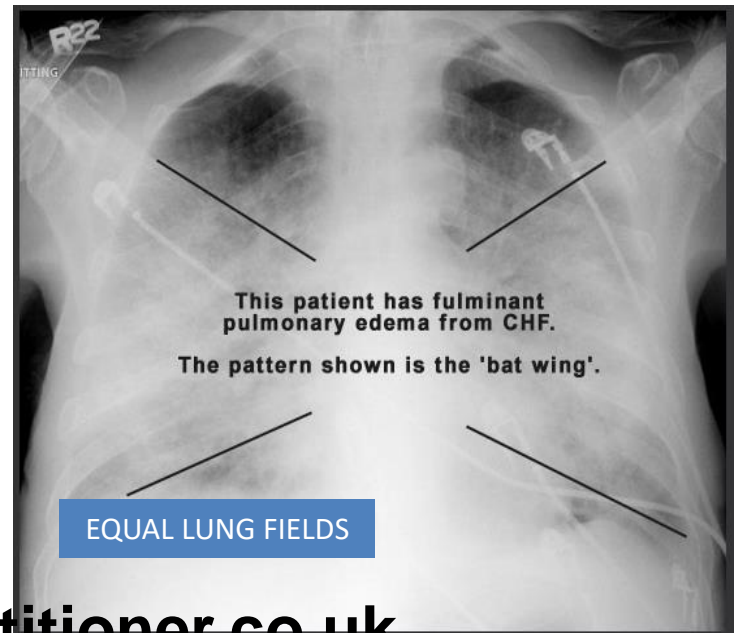
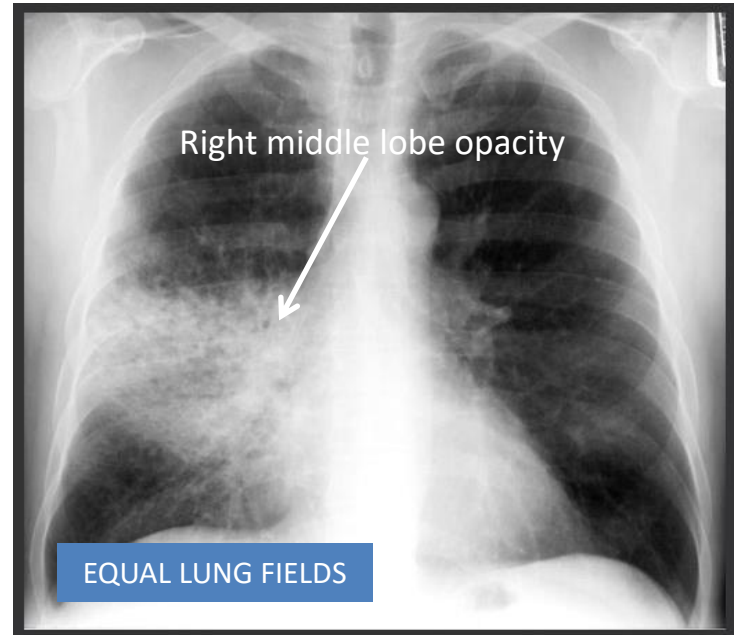




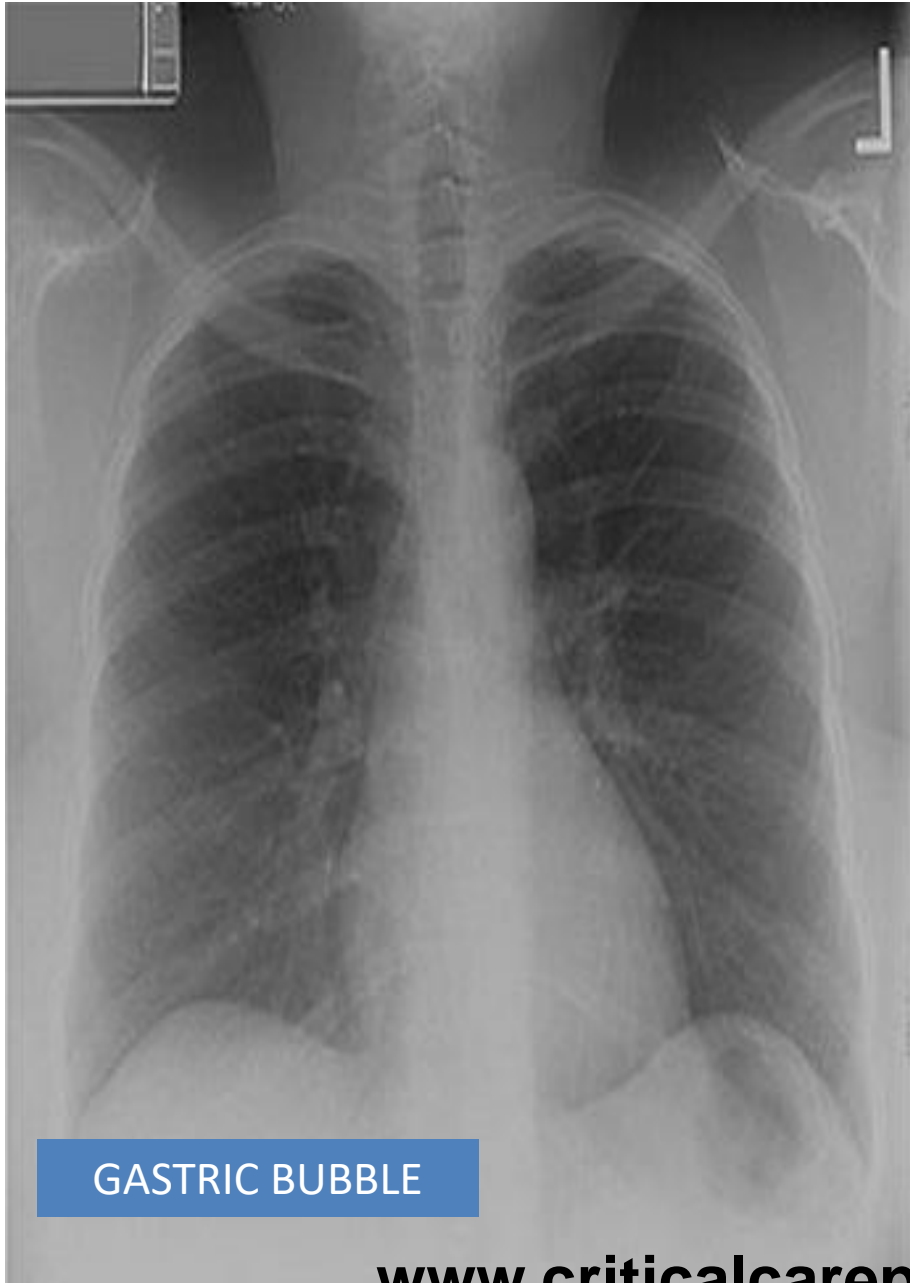




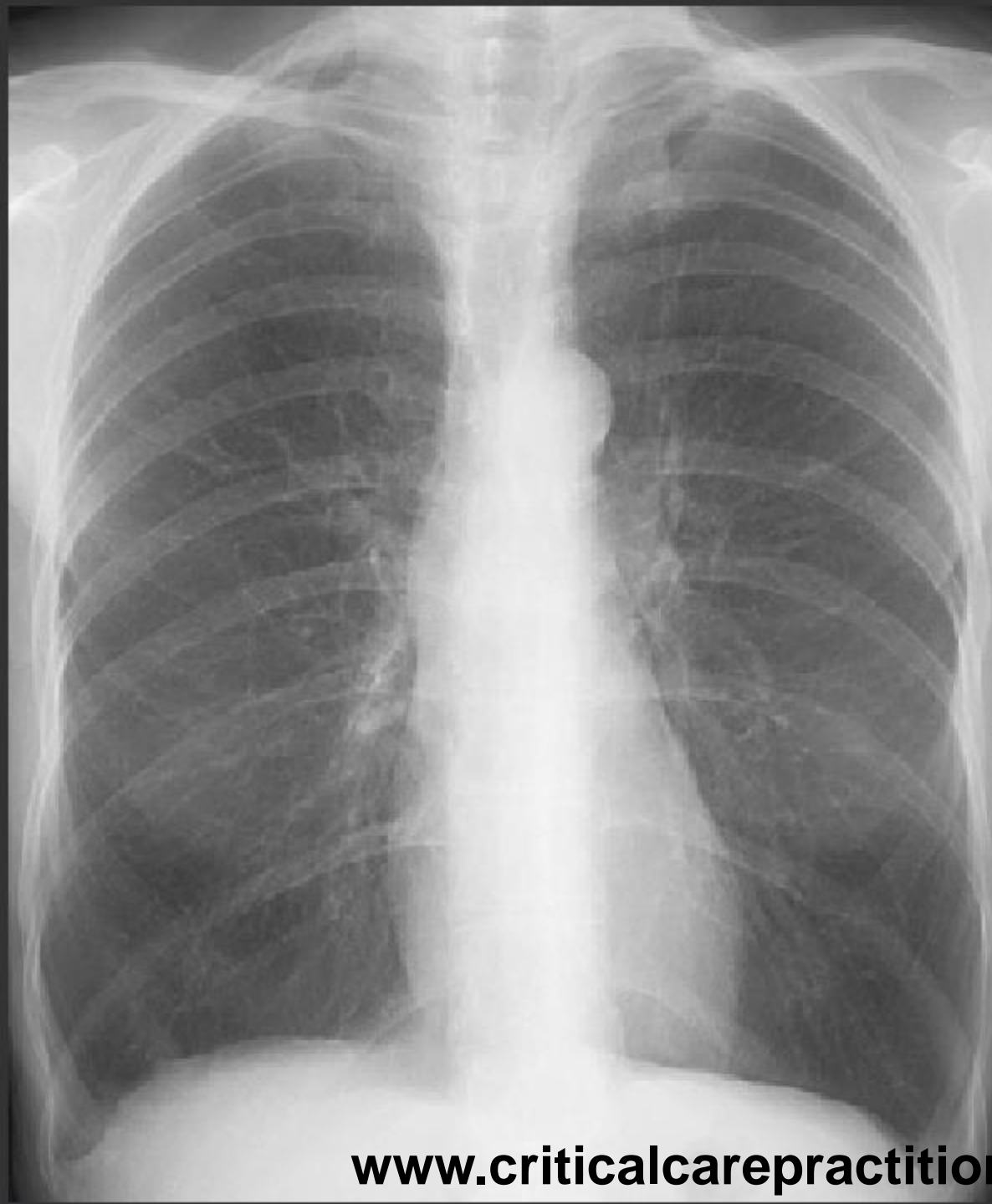




GASTRIC BUBBLE



A

B

C

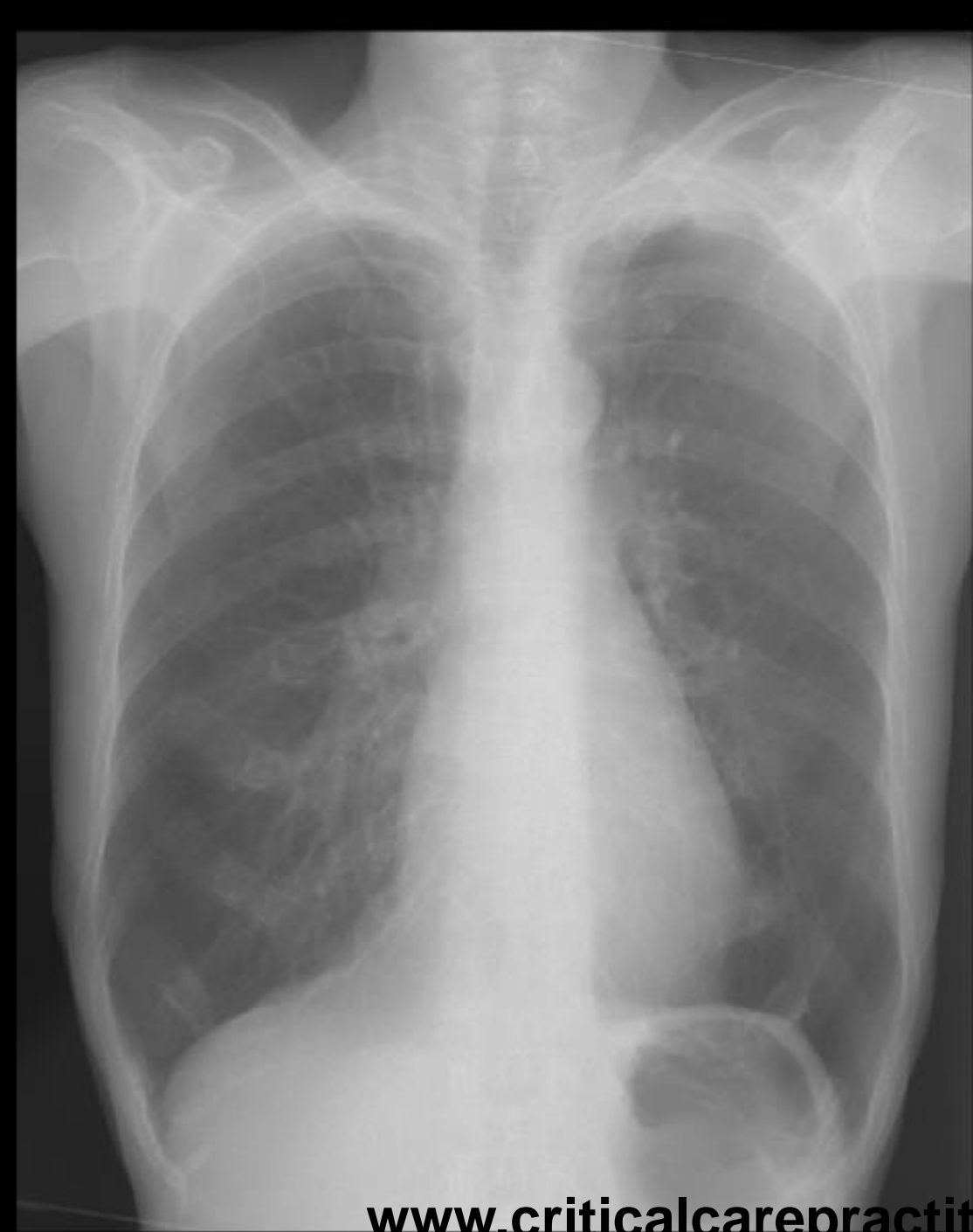D

E

F

G

Your Turn!



A

B

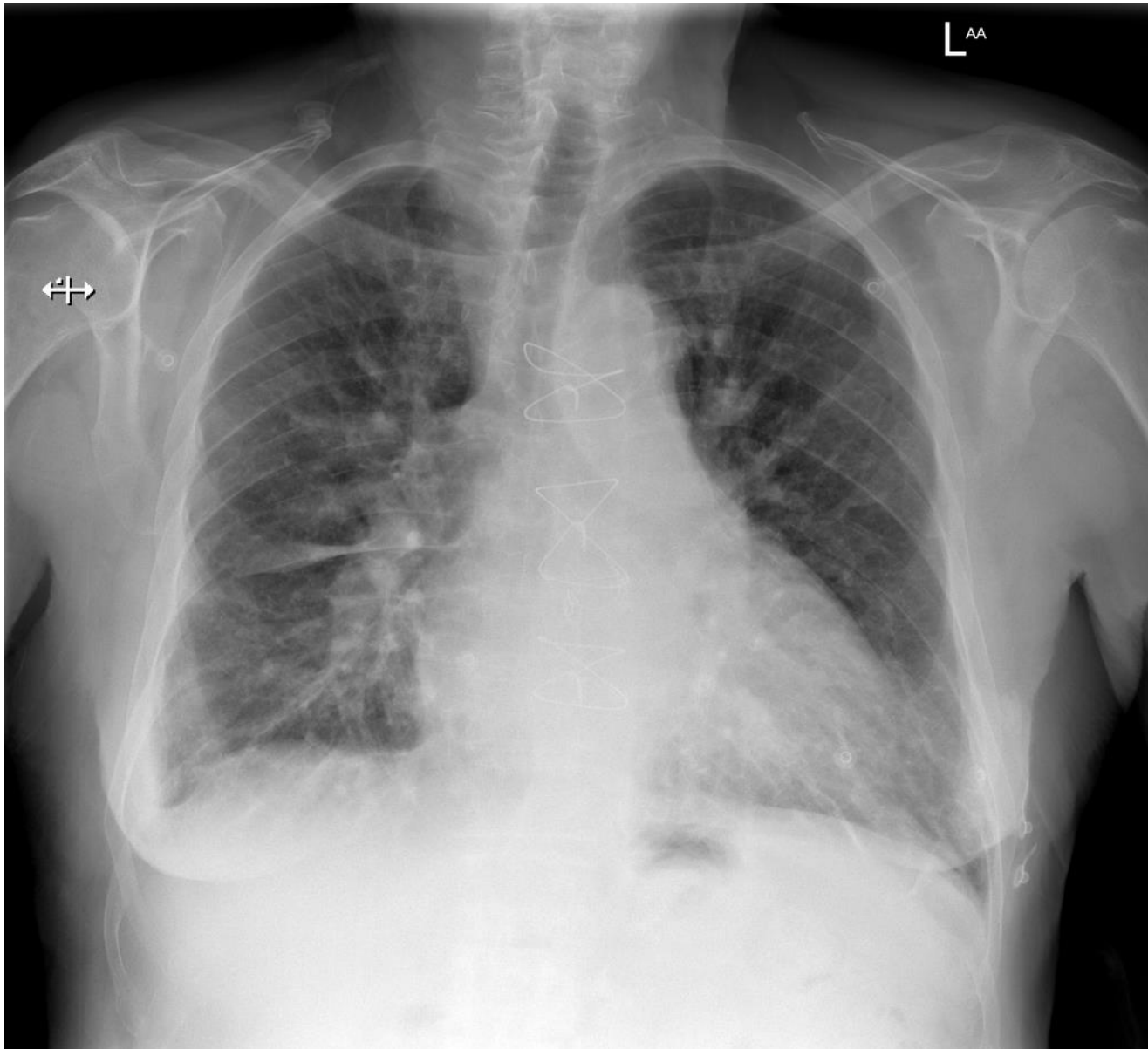
C

D

E

F

G



A

B

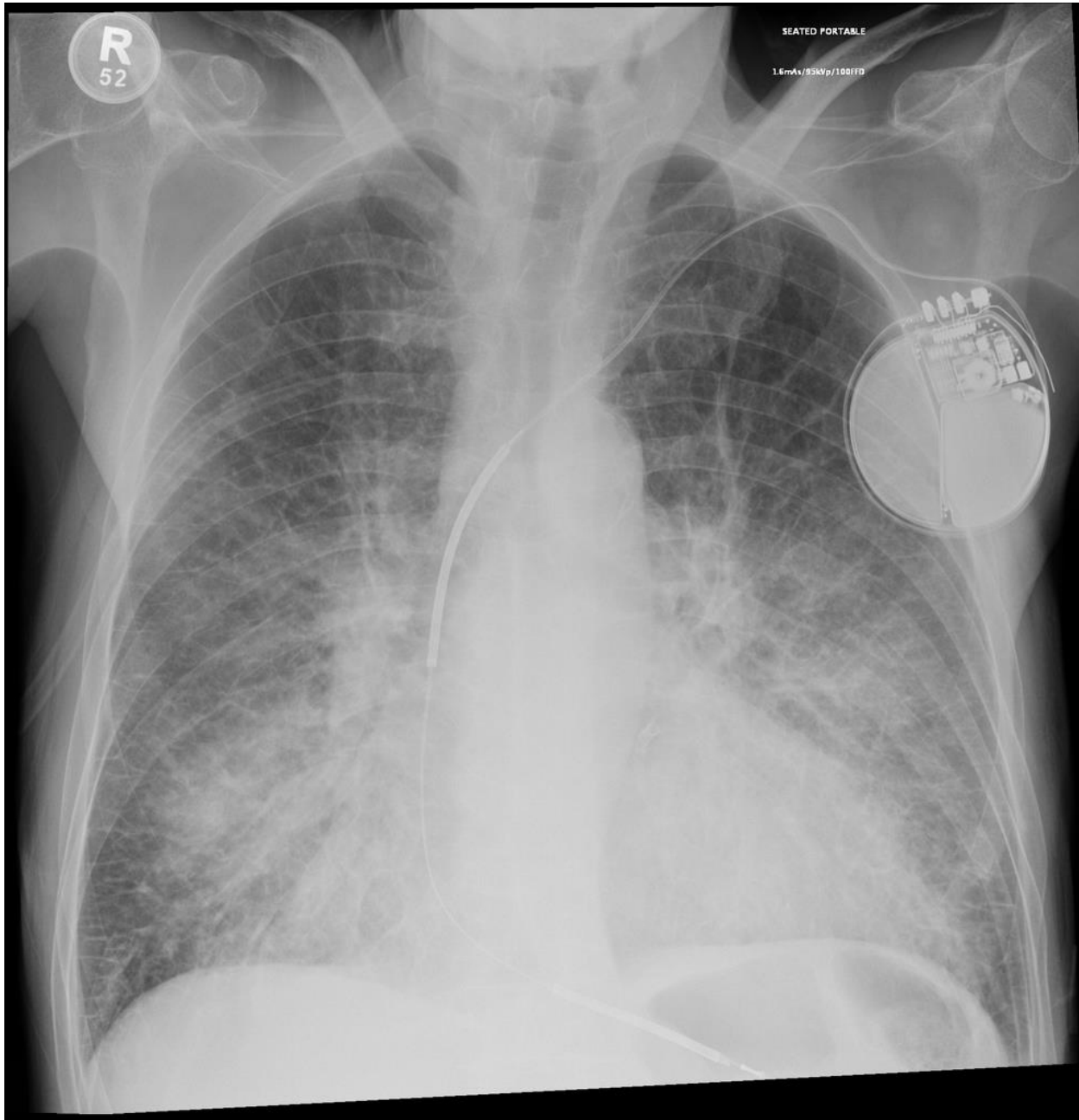
C

D

E

F

G



A

B

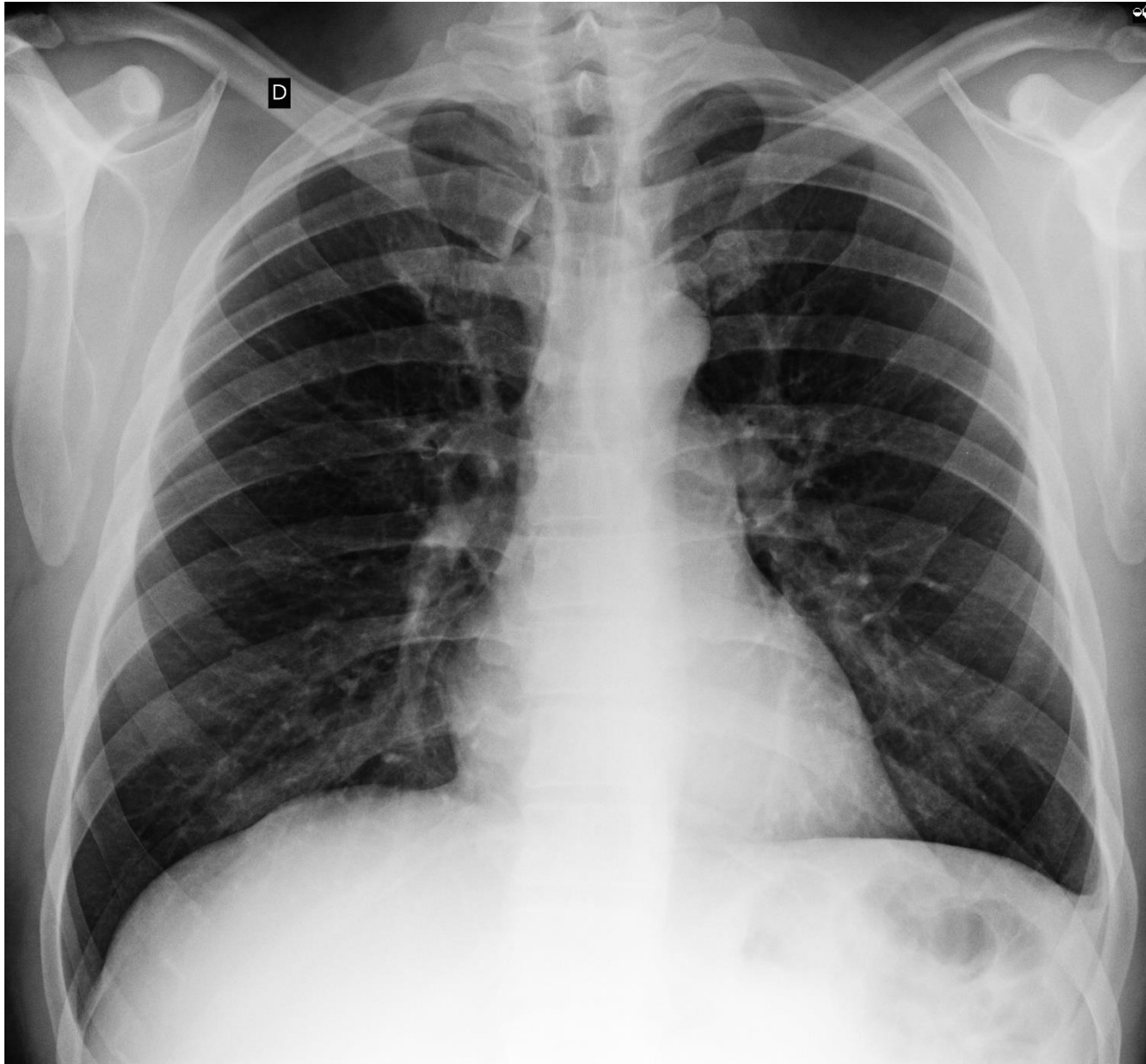
C

D

E

F

G



A

B

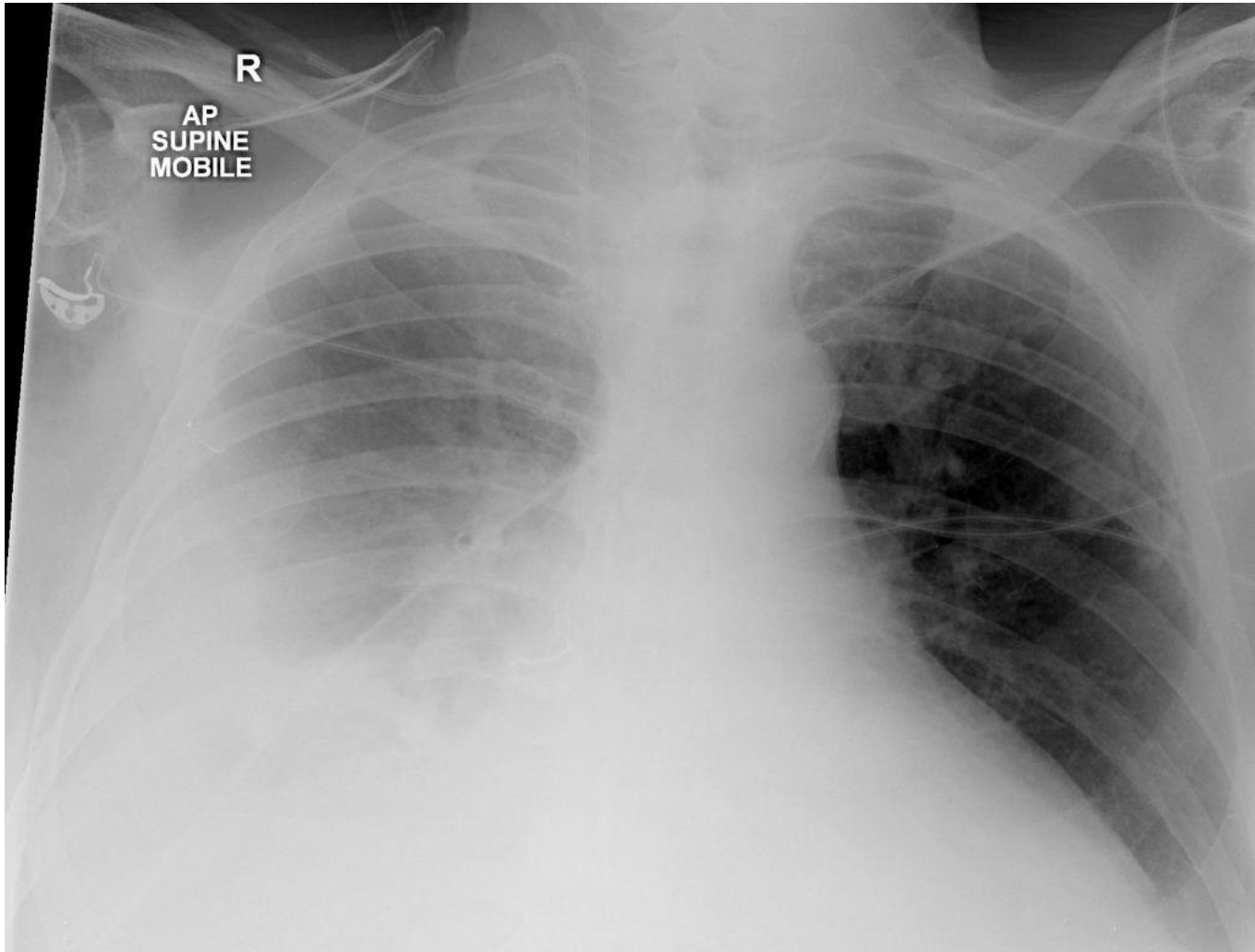
C

D

E

F

G



A

B

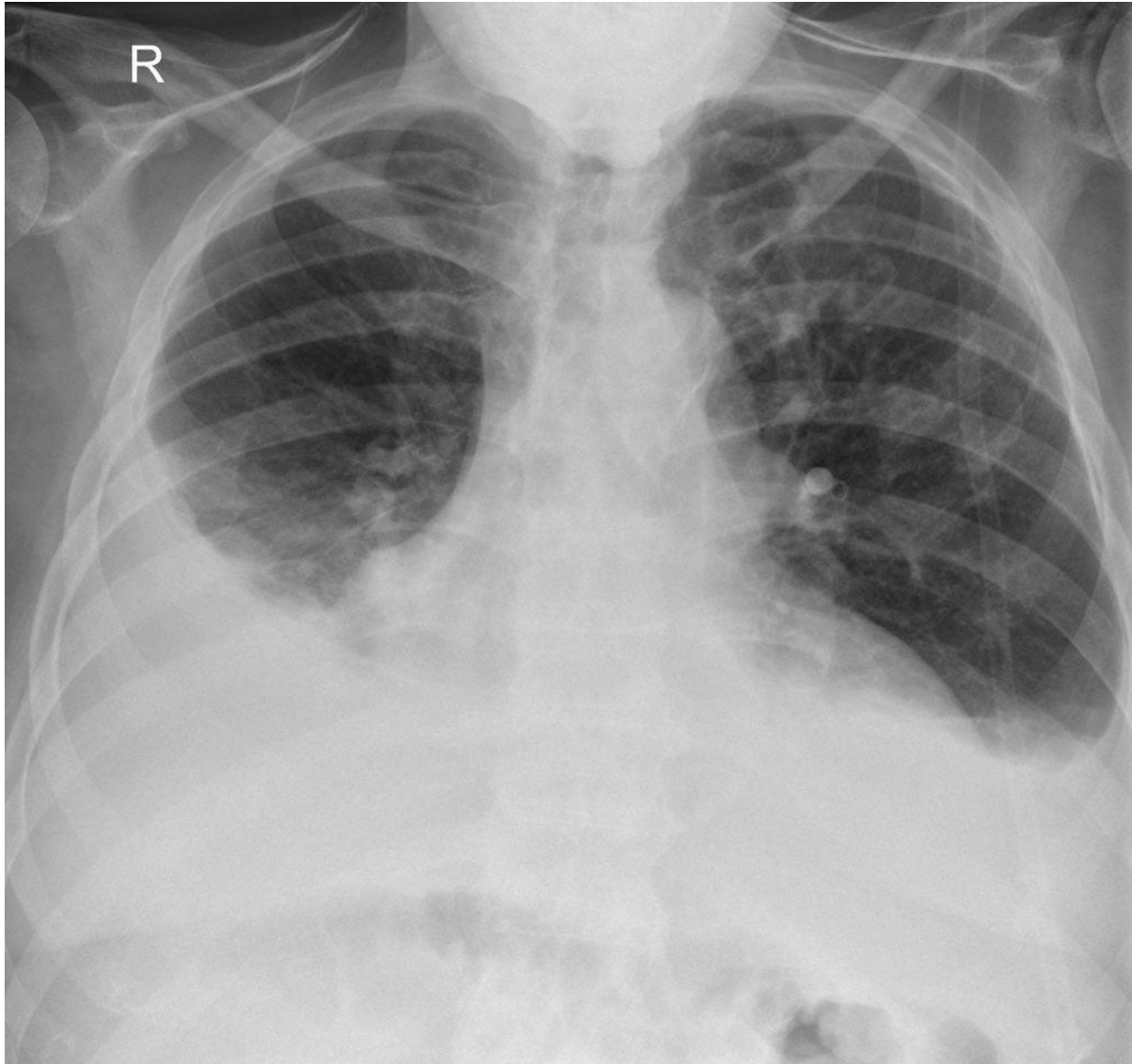
C

D

E

F

G



A

B

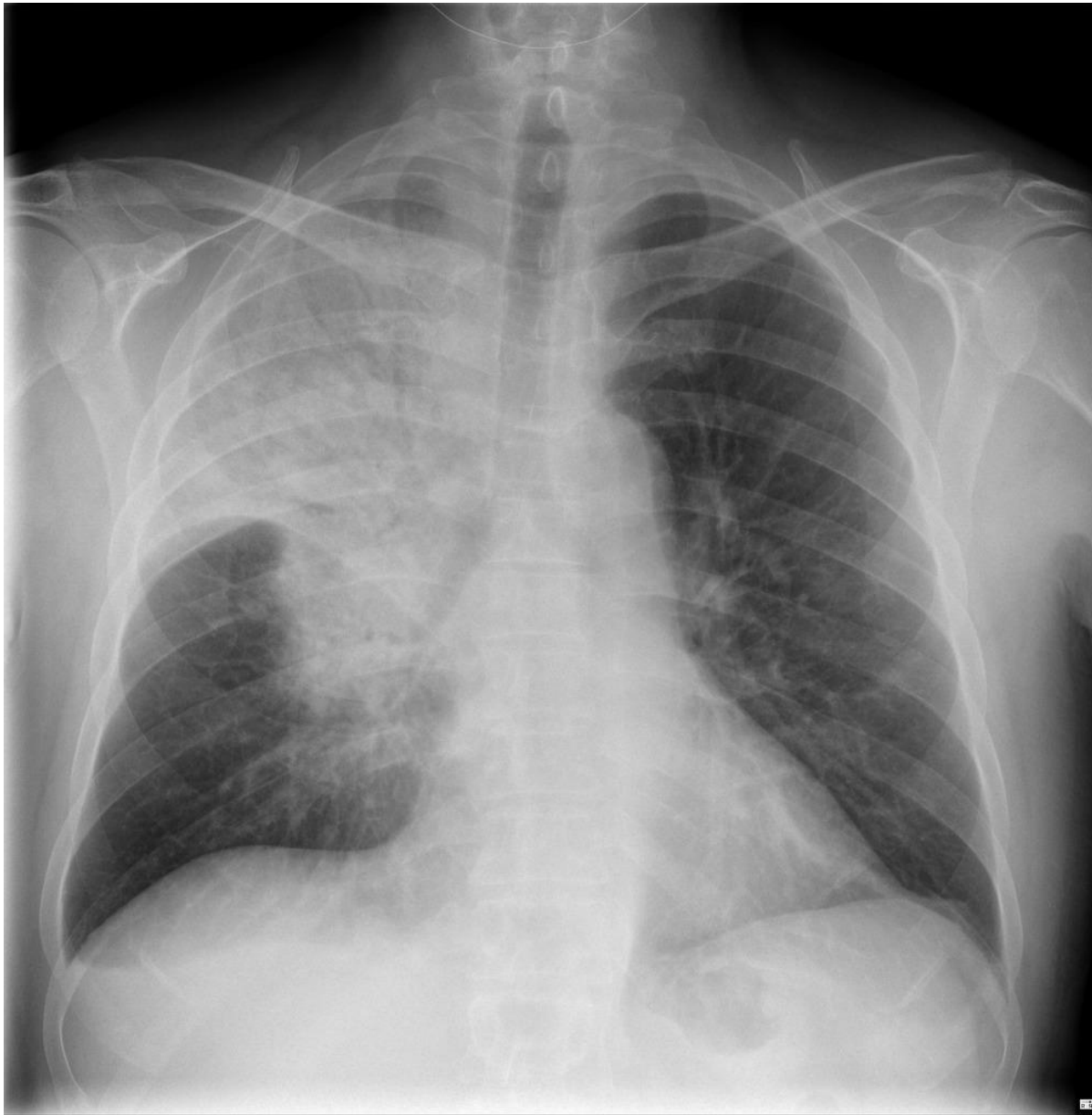C

D

E

F

G



A

B

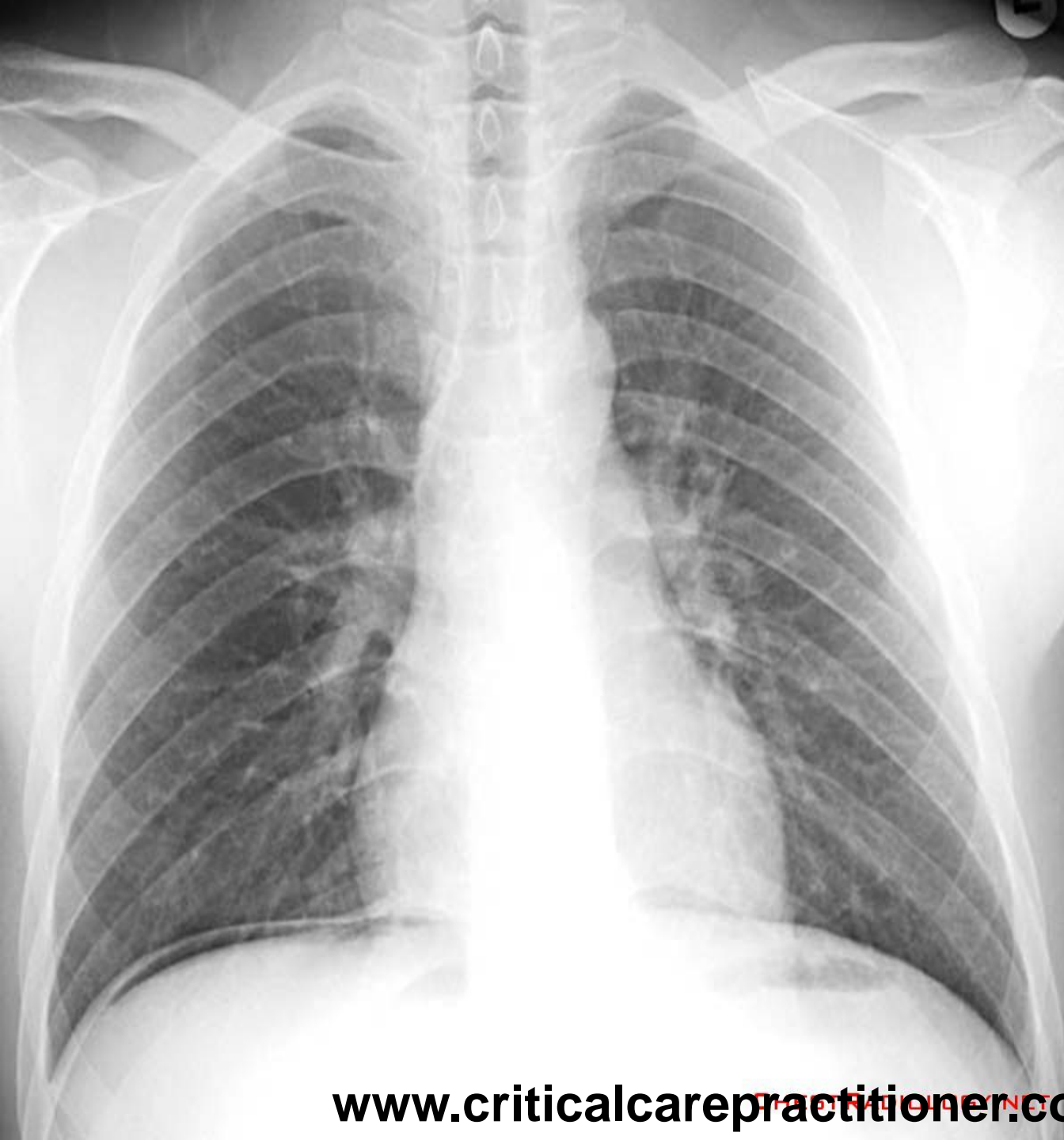C

D

E

F

G



A

B

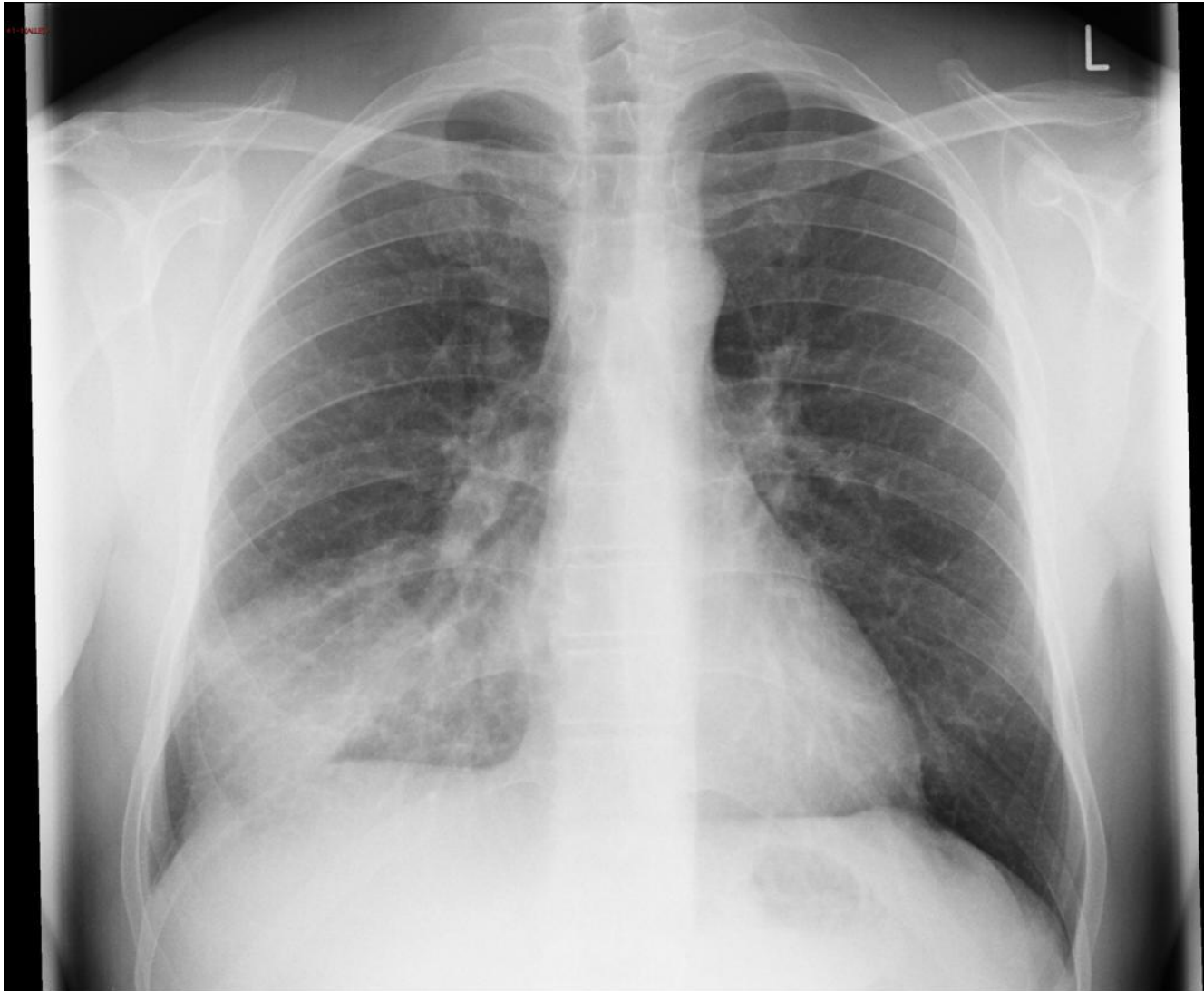
C

D

E

F

G



A

B

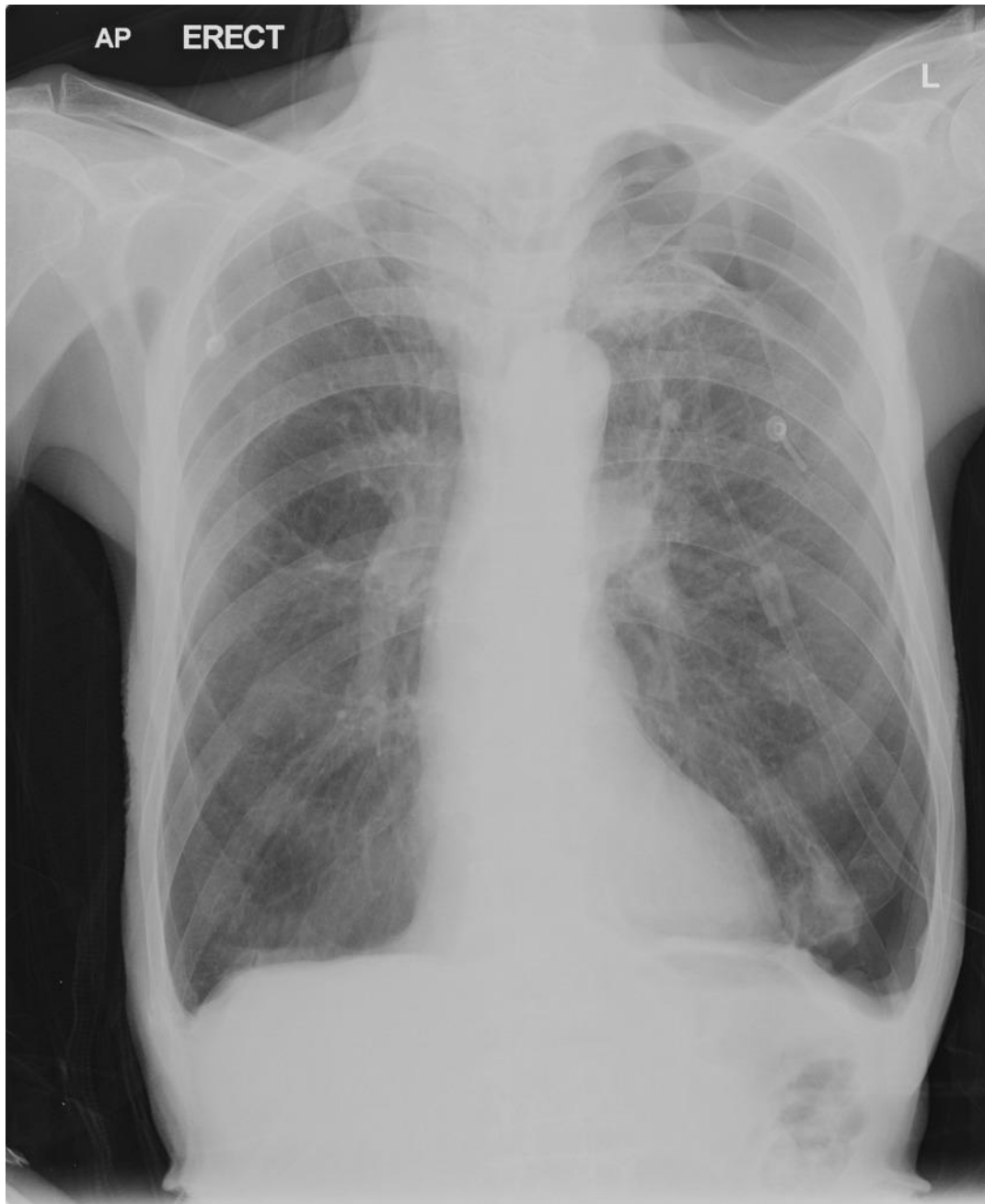C

D

E

F

G



A

B

C

D

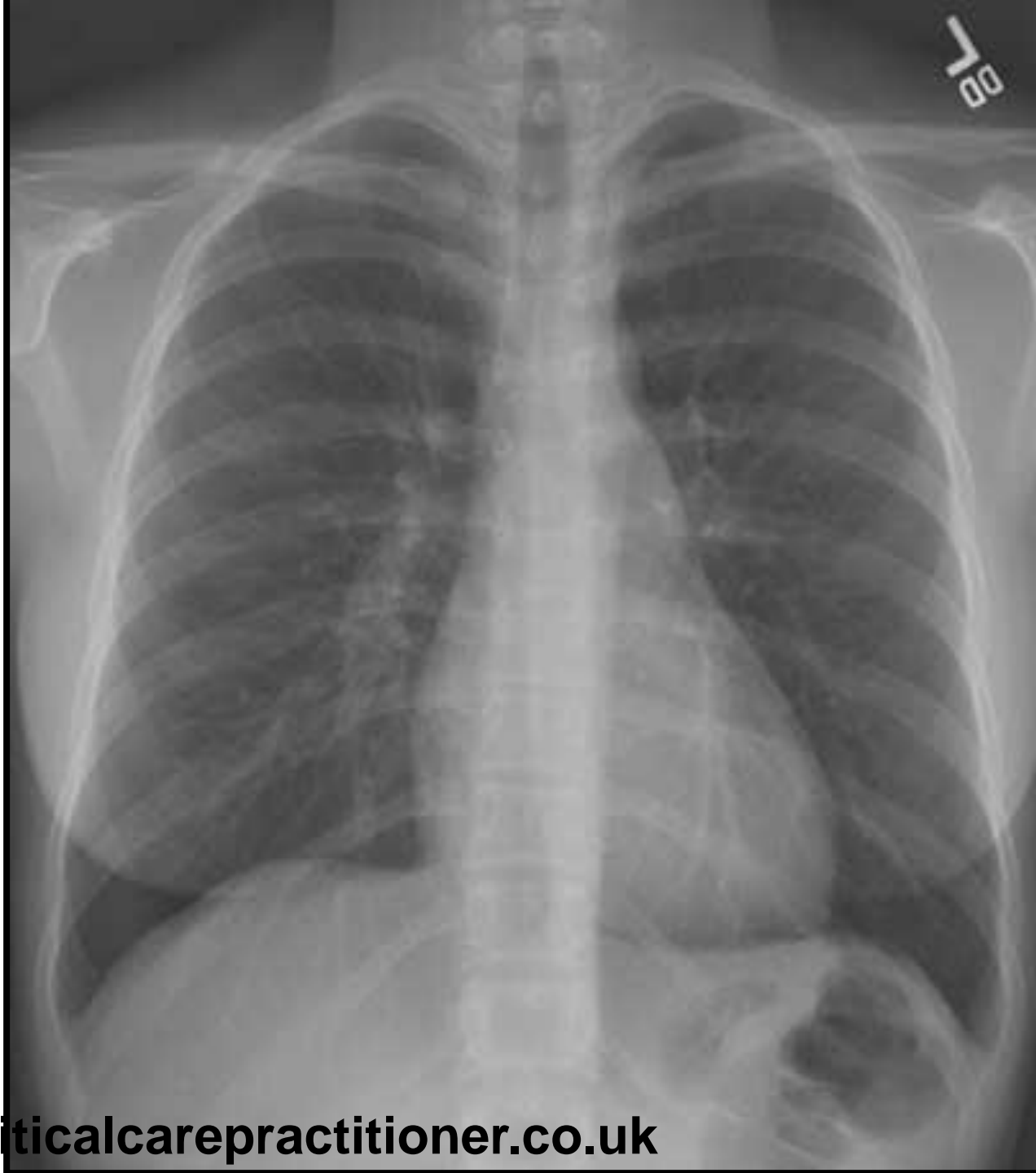E

F

G

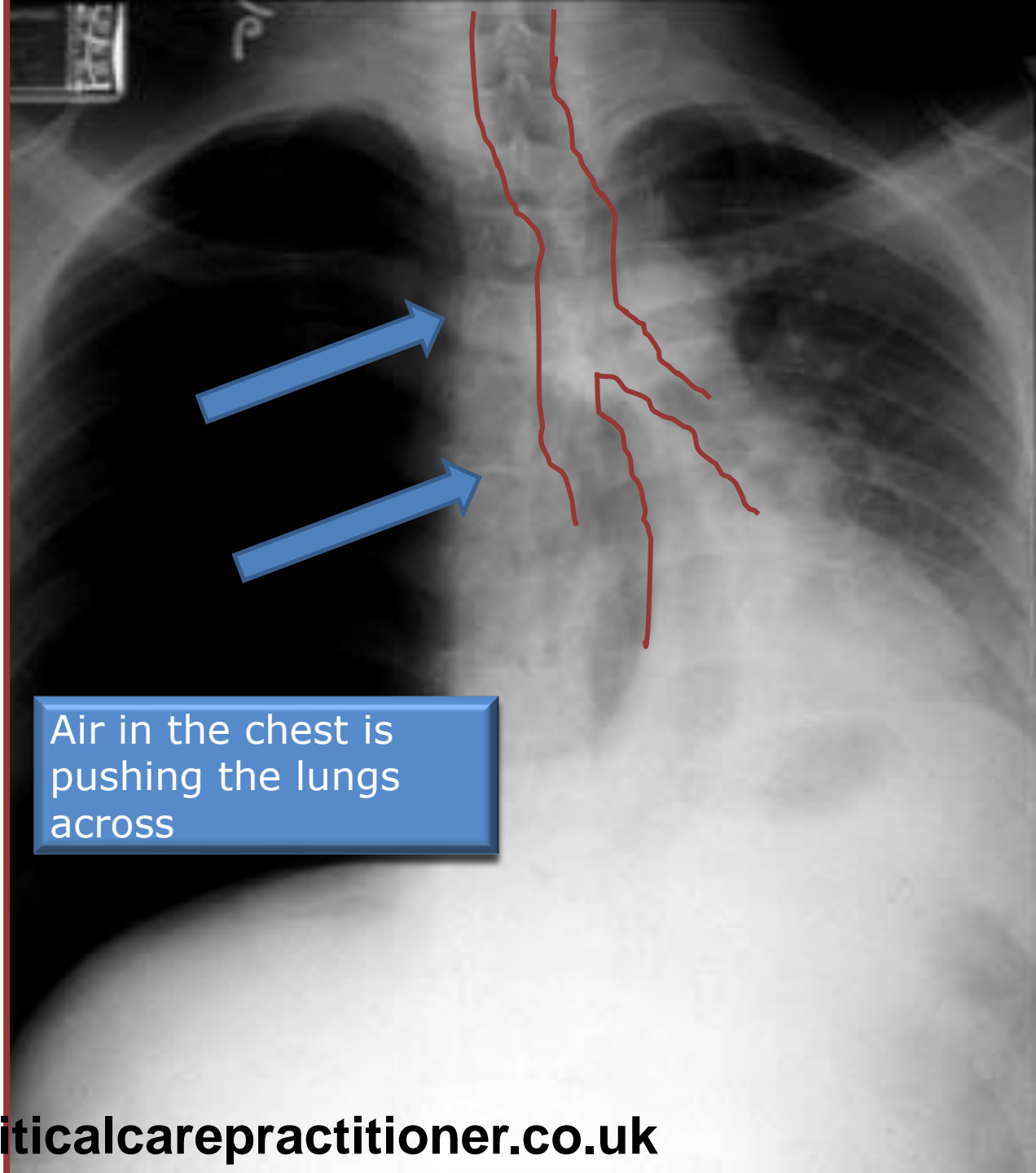
Chest X Rays part II

- Orientation
- Patient details
- Technicals
- Bone
- Trachea
- Heart
- Mediastinum
- Hilum
- Lungs
- Fissures
- Diaphragm
- Soft tissue
- Below diaphragm
- Hidden areas



Tracheal deviation

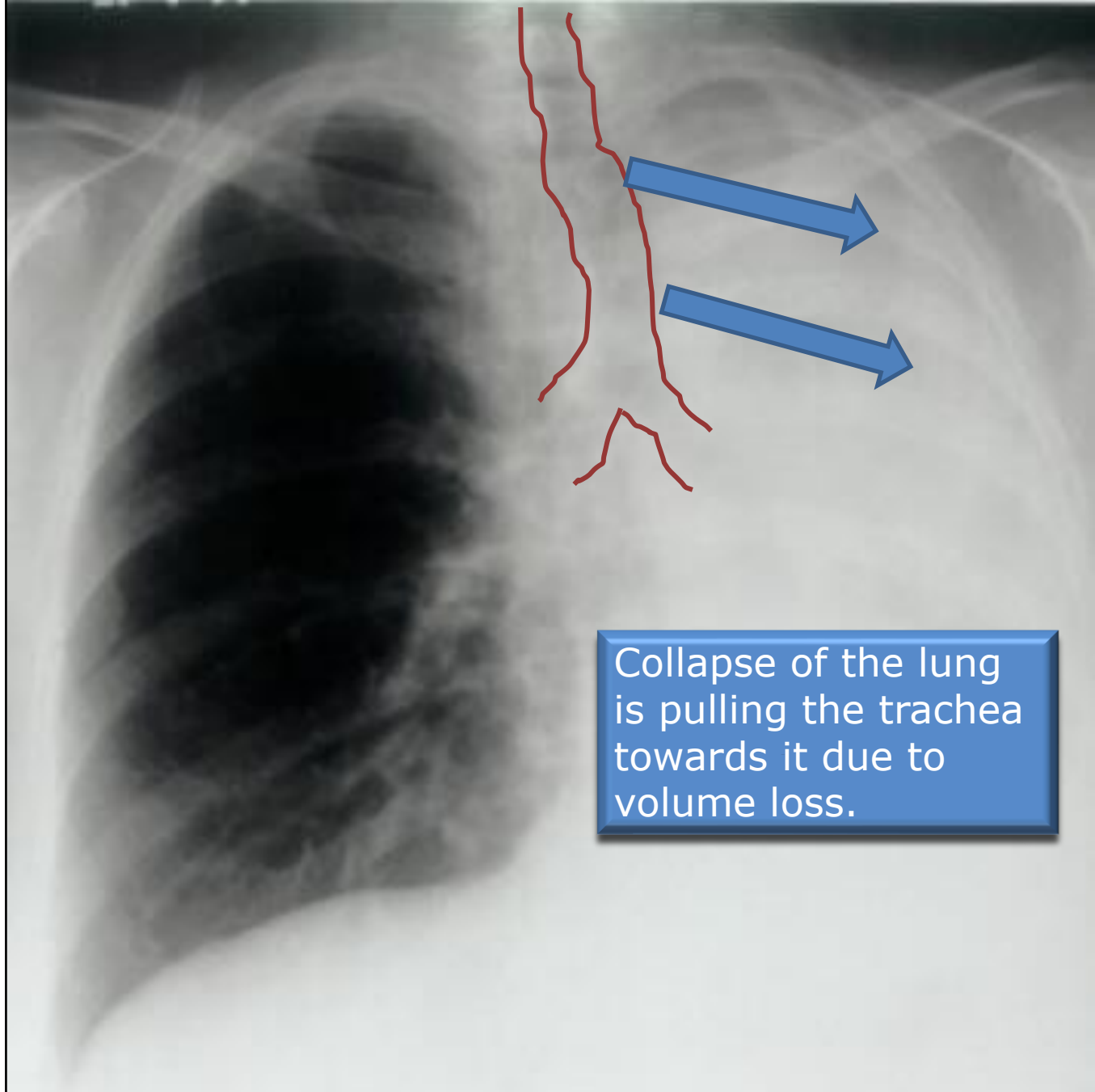
- Orientation
- Patient details
- Technicals
- Bone
- Trachea
- Heart
- Mediastinum
- Hilum
- Lungs
- Fissures
- Diaphragm
- Soft tissue
- Below diaphragm
- Hidden areas



Air in the chest is pushing the lungs across

Tracheal deviation

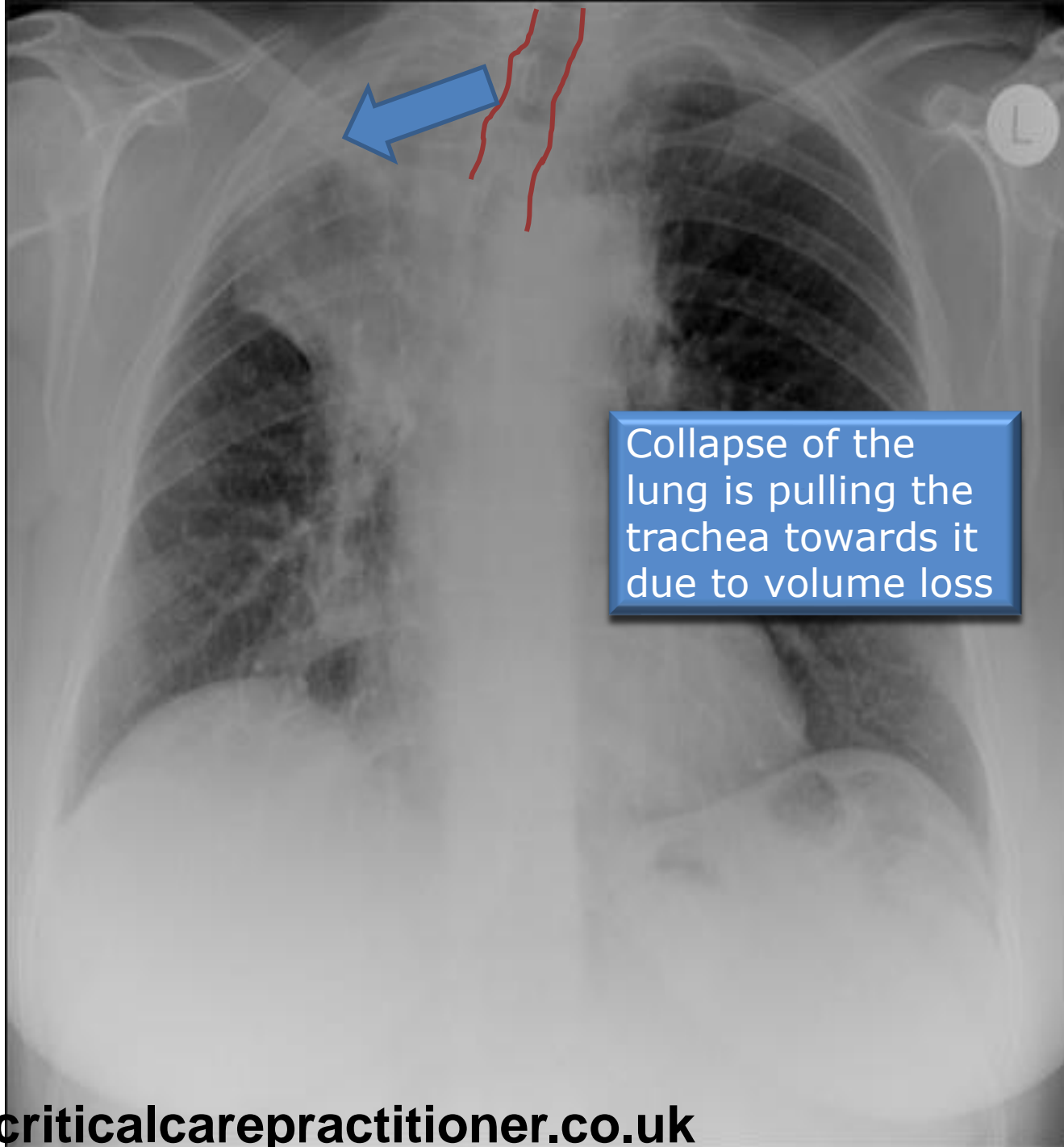
- Orientation
- Patient details
- Technicals
- Bone
- Trachea
- Heart
- Mediastinum
- Hilum
- Lungs
- Fissures
- Diaphragm
- Soft tissue
- Below diaphragm
- Hidden areas



Collapse of the lung is pulling the trachea towards it due to volume loss.

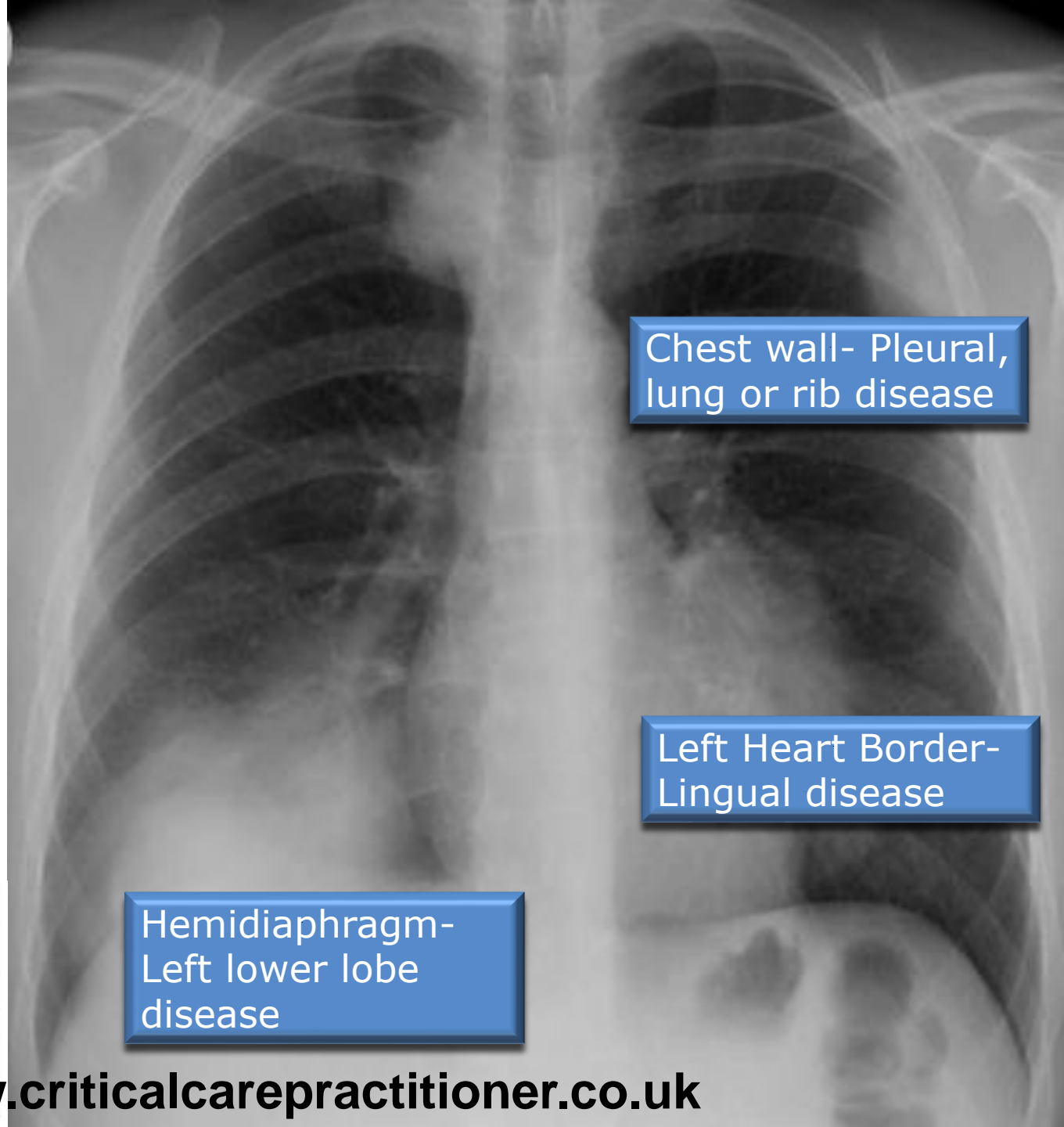
Tracheal deviation

- Orientation
- Patient details
- Technicals
- Bone
- Trachea
- Heart
- Mediastinum
- Hilum
- Lungs
- Fissures
- Diaphragm
- Soft tissue
- Below diaphragm
- Hidden areas



Silhouette sign

- Orientation
- Patient details
- Technicals
- Bone
- Trachea
- Heart
- Mediastinum
- Hilum
- Lungs
- Fissures
- Diaphragm
- Soft tissue
- Below diaphragm
- Hidden areas



Chest wall- Pleural,
lung or rib disease

Left Heart Border-
Lingual disease

Hemidiaphragm-
Left lower lobe
disease

Right middle lobe	Right heart border
Right upper lobe	Right Mediastinum
Right lower lobe	Right hemidiaphragm
Left upper lobe	Aortic knuckle
Lingula	Left heart border
Left lower lobe	Left hemidiaphragm

Silhouette sign

- Orientation
- Patient details
- Technicals
- Bone
- Trachea
- Heart
- Mediastinum
- Hilum
- Lungs
- Fissures
- Diaphragm
- Soft tissue
- Below
- Hidden areas

Density above
horizontal fissure-
Anterior segment of
the right upper lobe

Aortic knuckle-
anterior
mediastinal or left
upper lobe disease

Right heart border-
middle lobe disease

Paraspinal line -
Posterior thorax disease

Right middle lobe	Right heart border
Right upper lobe	Right Mediastinum
Right lower lobe	Right hemidiaphragm
Left upper lobe	Aortic knuckle
Lingula	Left heart border
Left lower lobe	Left hemidiaphragm

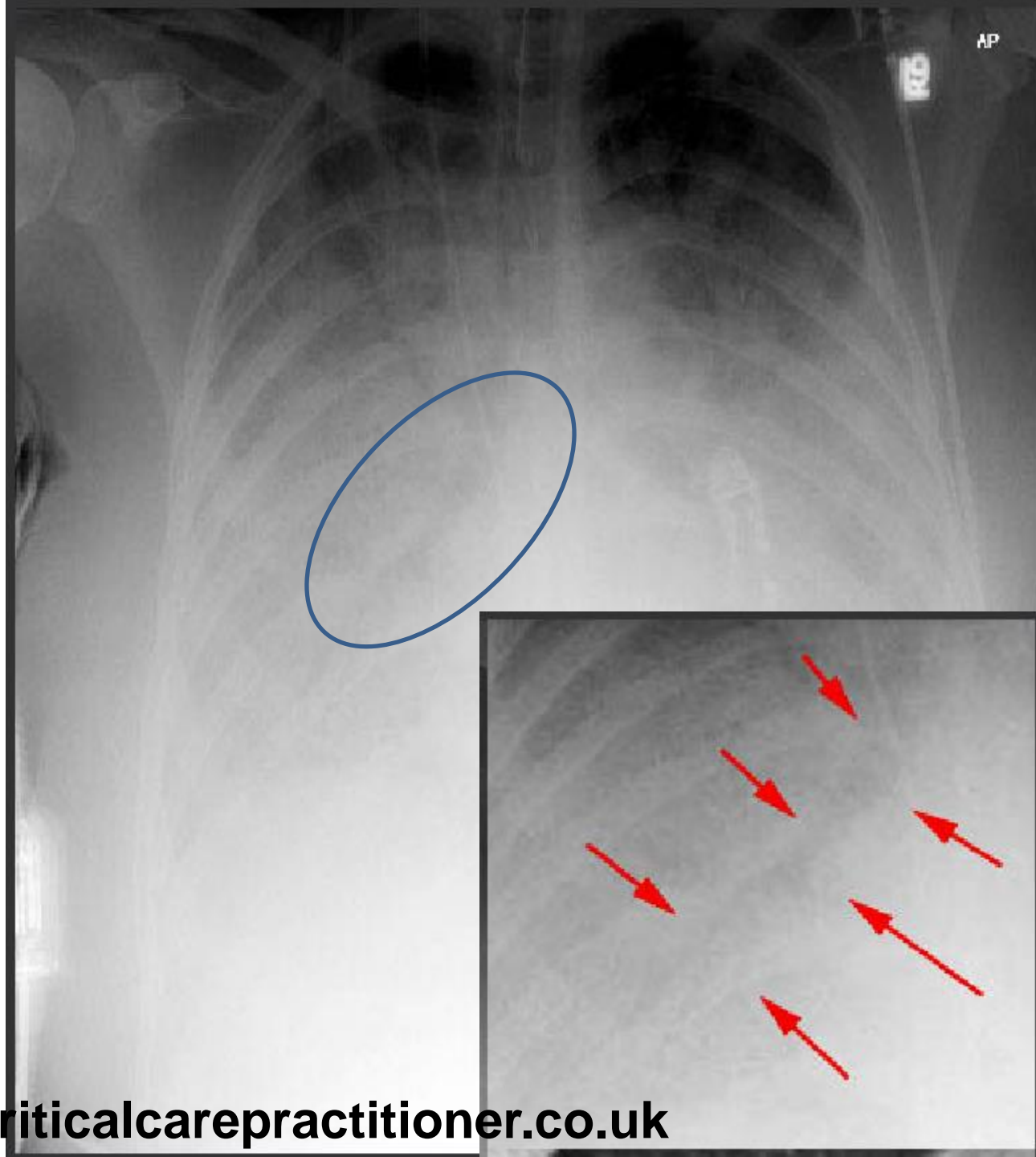
Consolidation

Lungs filling with:

- Blood
- Fluid
- Pus

Air Bronchogram

- Orientation
- Patient details
- Technicals
- Bone
- Trachea
- Heart
- Mediastinum
- Hilum
- Lungs
- Fissures
- Diaphragm
- Soft tissue
- Below diaphragm
- Hidden areas

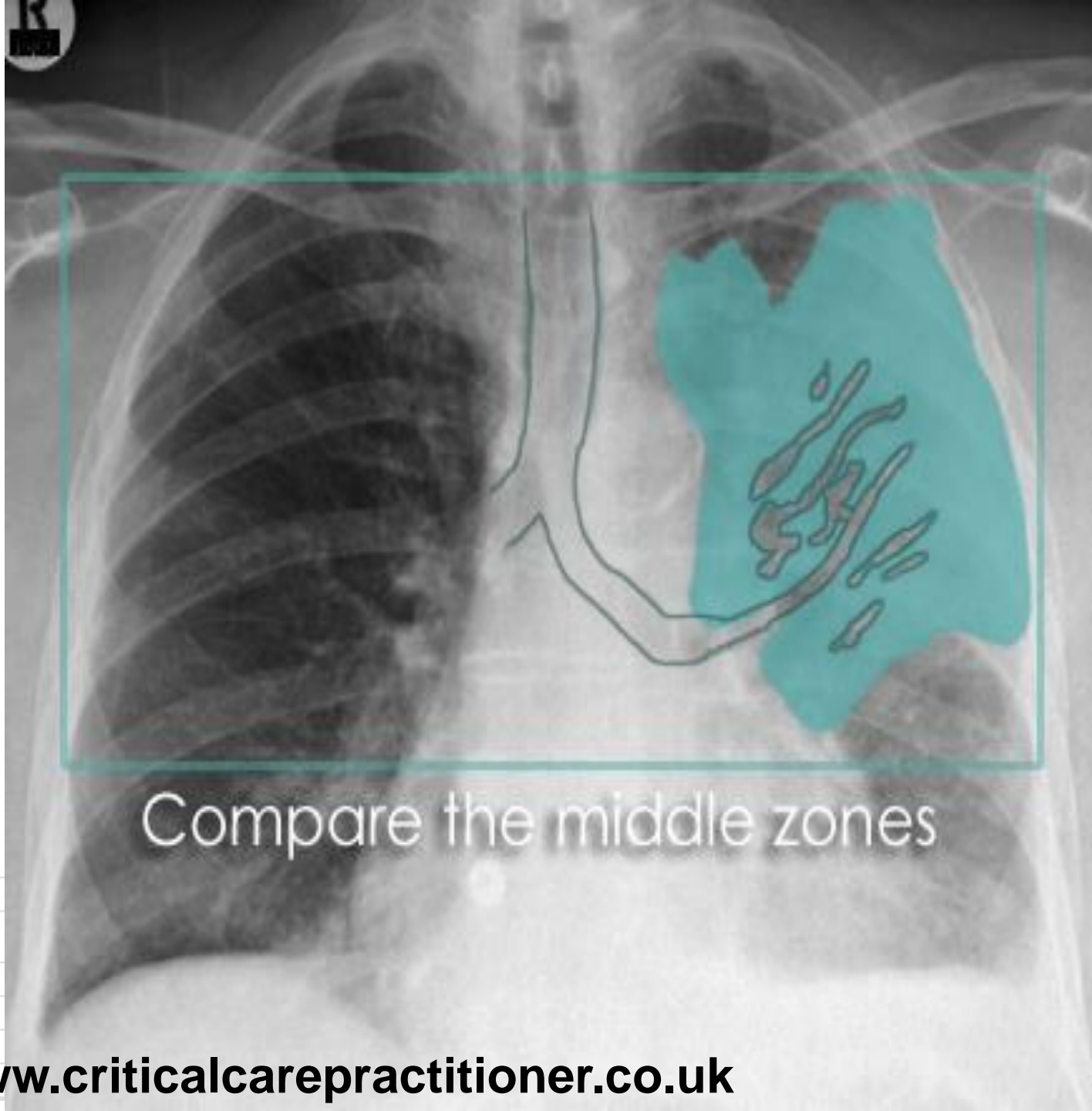


Consolidation

Lungs filling with:

- Blood
- Fluid
- Pus

Air Bronchogram



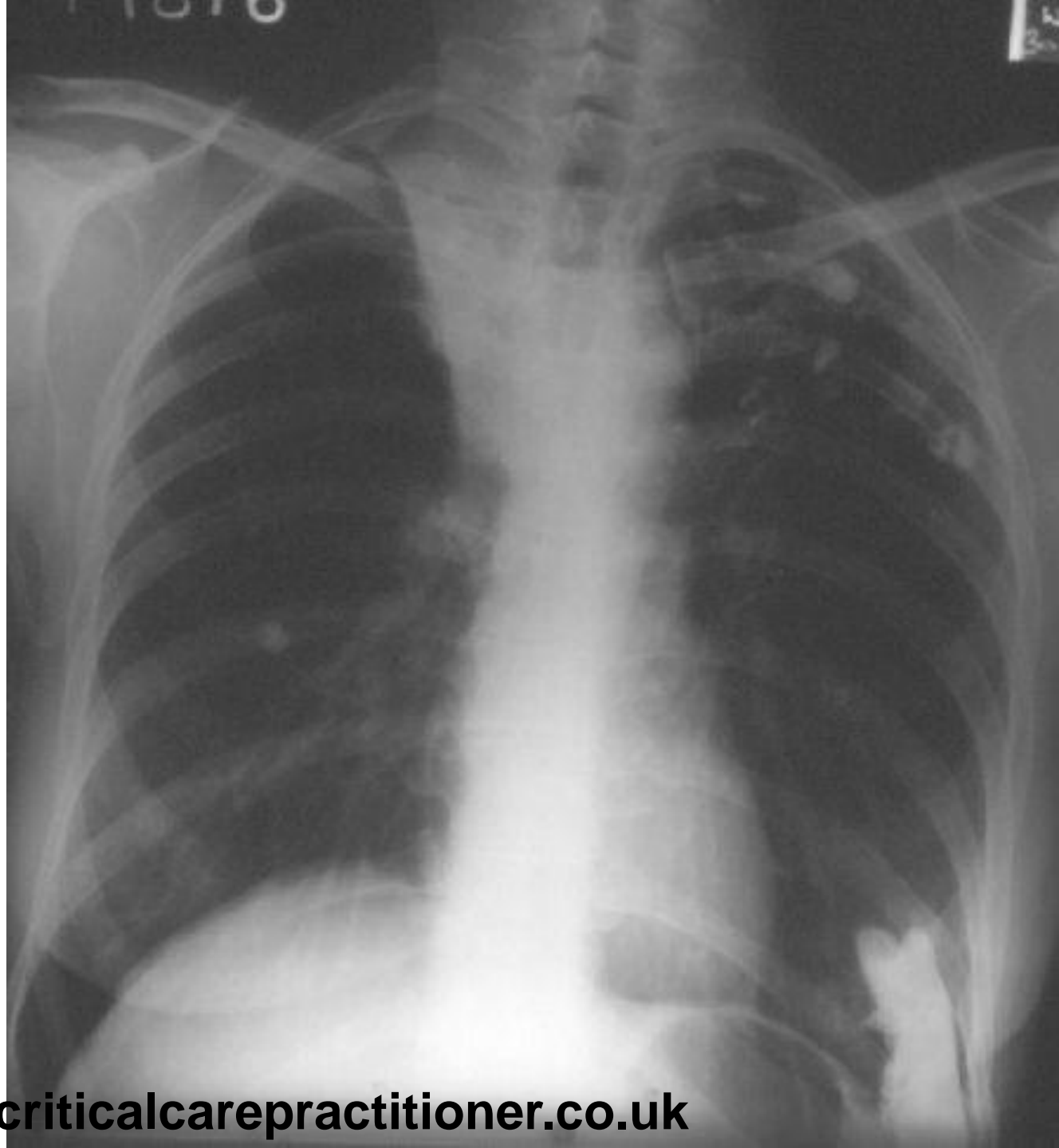
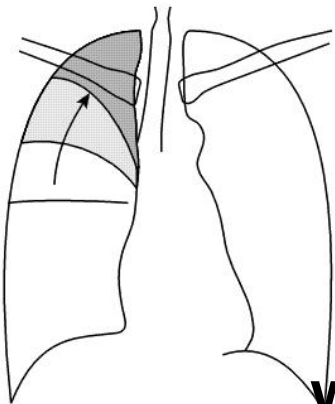
Compare the middle zones

Right middle lobe	Right heart border
Right upper lobe	Right Mediastinum
Right lower lobe	Right hemidiaphragm
Left upper lobe	Aortic knuckle
Lingula	Left heart border
Left lower lobe	Left hemidiaphragm

Collapse

Right upper lobe collapse

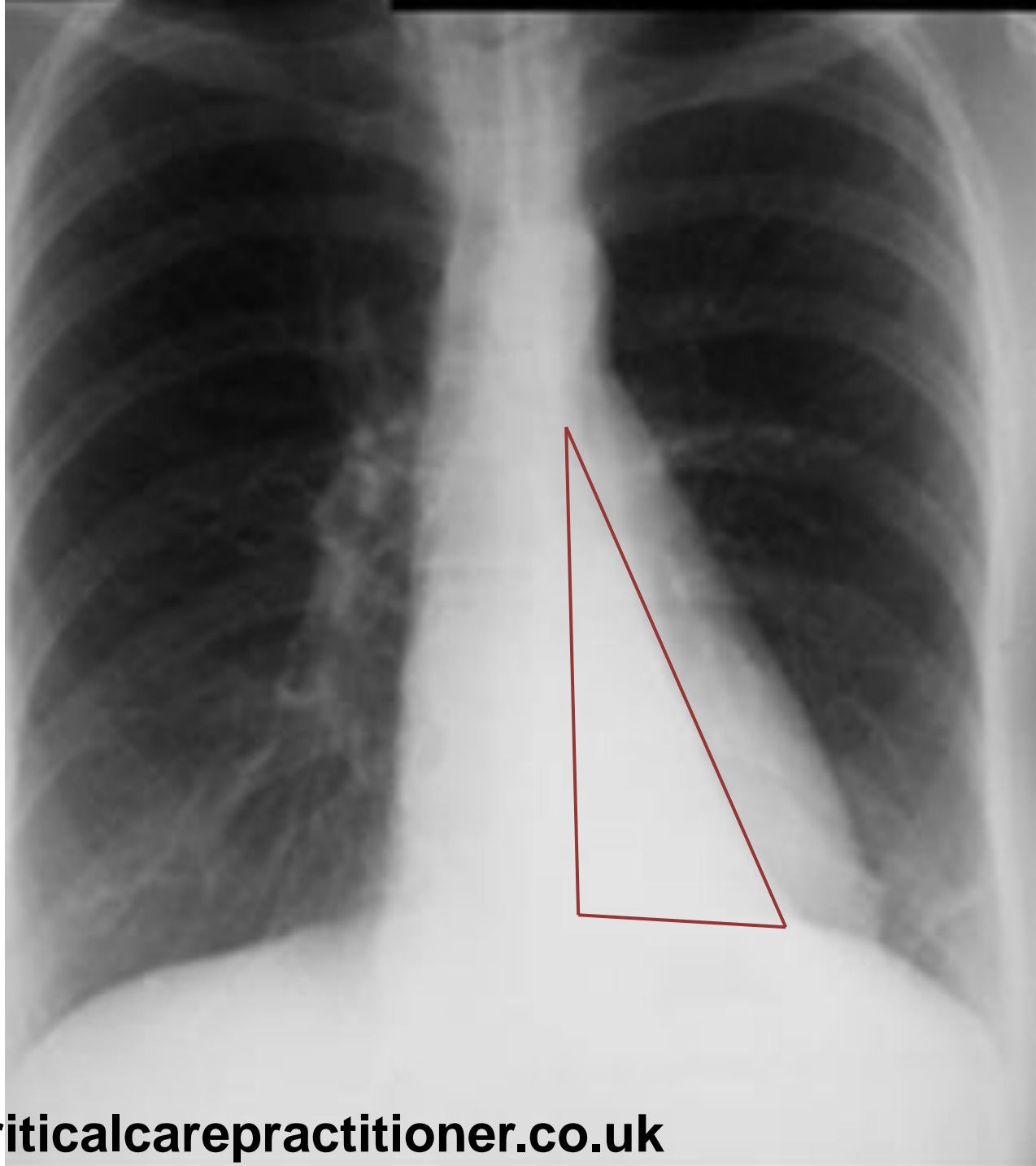
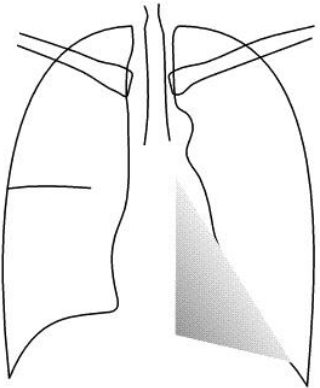
- Orientation
- Patient details
- Technicals
- Bone
- Trachea
- Heart
- Mediastinum
- Hilum
- Lungs
- Fissures
- Diaphragm
- Soft tissue
- Below diaphragm
- Hidden areas



Collapse

Left lower lobe collapse

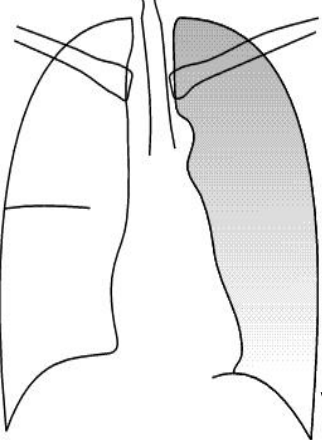
- Orientation
- Patient details
- Technicals
- Bone
- Trachea
- Heart
- Mediastinum
- Hilum
- Lungs
- Fissures
- Diaphragm
- Soft tissue
- Below diaphragm
- Hidden areas



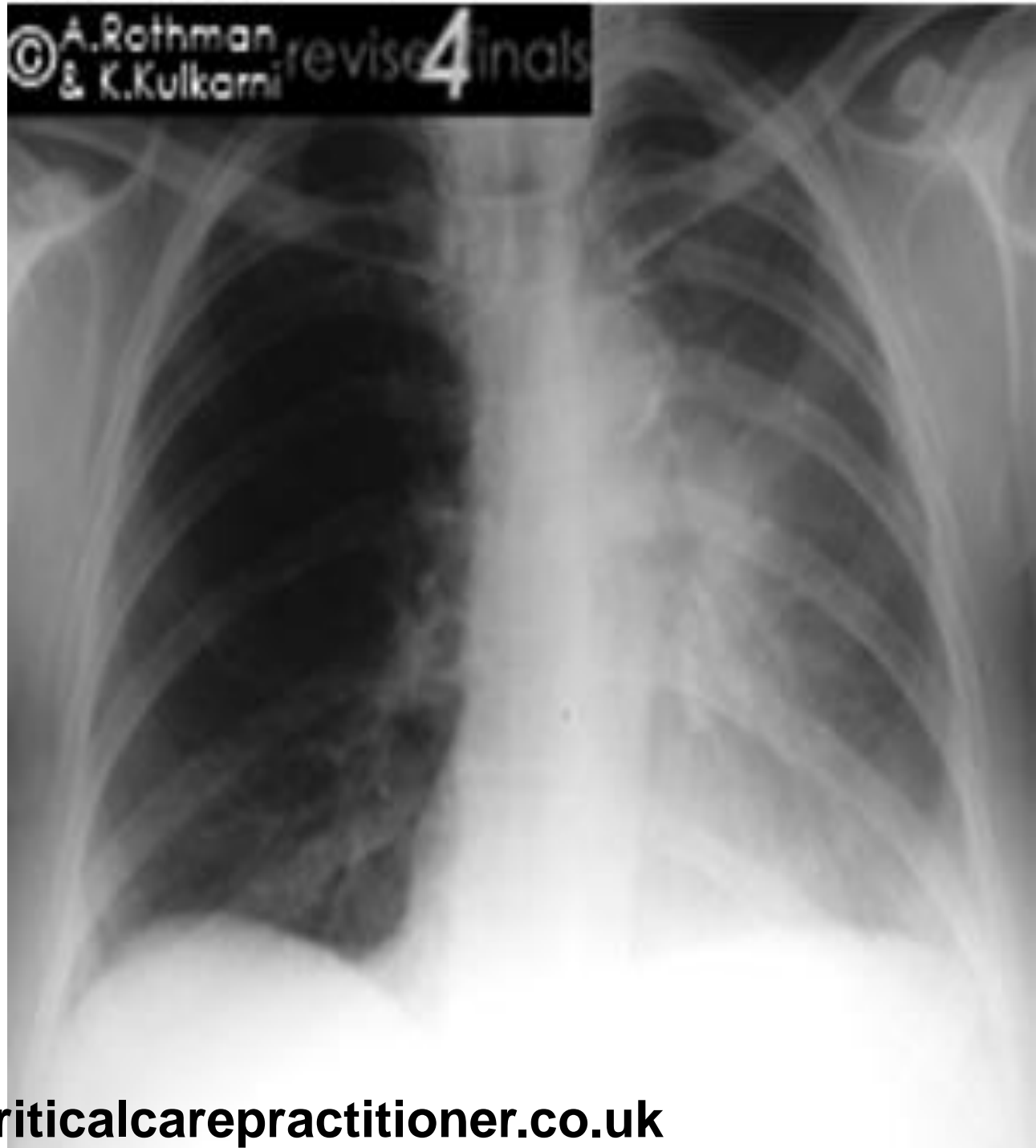
Collapse

Left upper lobe collapse

- Orientation
- Patient details
- Technicals
- Bone
- Trachea
- Heart
- Mediastinum
- Hilum
- Lungs
- Fissures
- Diaphragm
- Soft tissue
- Below diaphragm
- Hidden areas



© A. Rothman & K. Kulkarni revise4inals



This 68 year old gentleman presented with gradual onset shortness of breath and frothy sputum.

Examination of the chest:

Displaced apex beat, raised JVP, diminished breath sounds and stony dull percussion at the lung bases bilaterally.

Enlarged heart.

High pressure in right side of heart

Fluid in the lung or between the surface and the lung

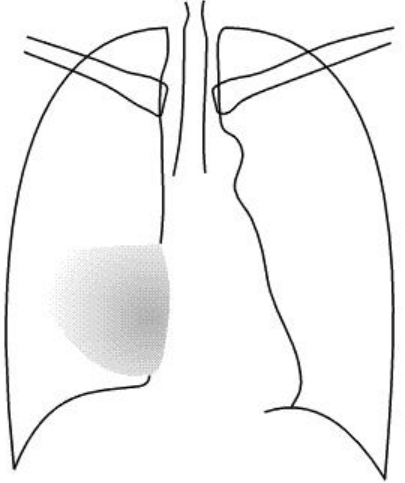
Stony dullness= pleural effusion

Congestive Cardiac failure with bilateral pleural effusions

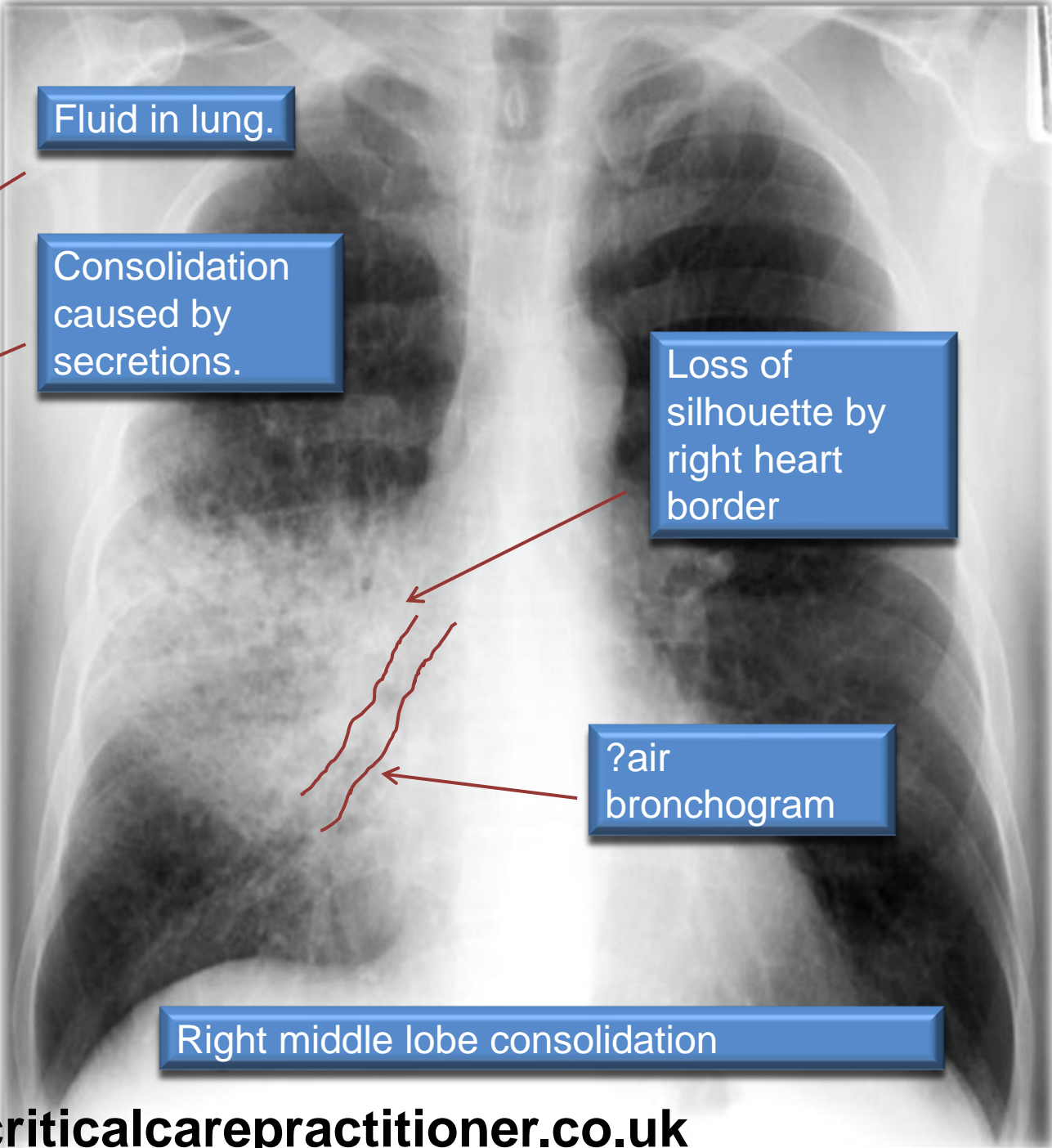
Right middle lobe	Right heart border
Right upper lobe	Right Mediastinum
Right lower lobe	Right hemidiaphragm
Left upper lobe	Aortic knuckle
Lingula	Left heart border
Left lower lobe	Left hemidiaphragm

This 83 year old gentleman presented with shortness of breath and increased sputum. Febrile and increased white cell count.

Examination of the chest:
Reduced air entry over right middle lobe. Crackles heard in inspiration



Right middle lobe	Right heart border
Right upper lobe	Right Mediastinum
Right lower lobe	Right hemidiaphragm
Left upper lobe	Aortic knuckle
Lingula	Left heart border
Left lower lobe	Left hemidiaphragm



Fluid in lung.

Consolidation caused by secretions.

Loss of silhouette by right heart border

?air bronchogram

Right middle lobe consolidation

This 74 year old gentleman presented with shortness of breath and poor saturations requiring oxygen.

On examination there is reduced air entry in both bases and a stony dullness

- Orientation
- Patient details
- Technicals
- Bone
- Trachea
- Heart
- Mediastinum
- Hilum
- Lungs
- Fissures
- Diaphragm
- Soft tissue
- Below diaphragm
- Hidden areas

